

20/20 and 20 mmHg. Can We Have Both?

Cataract Surgery in the Glaucoma Eye

WAVE 2026

Dr Geoffrey Chan

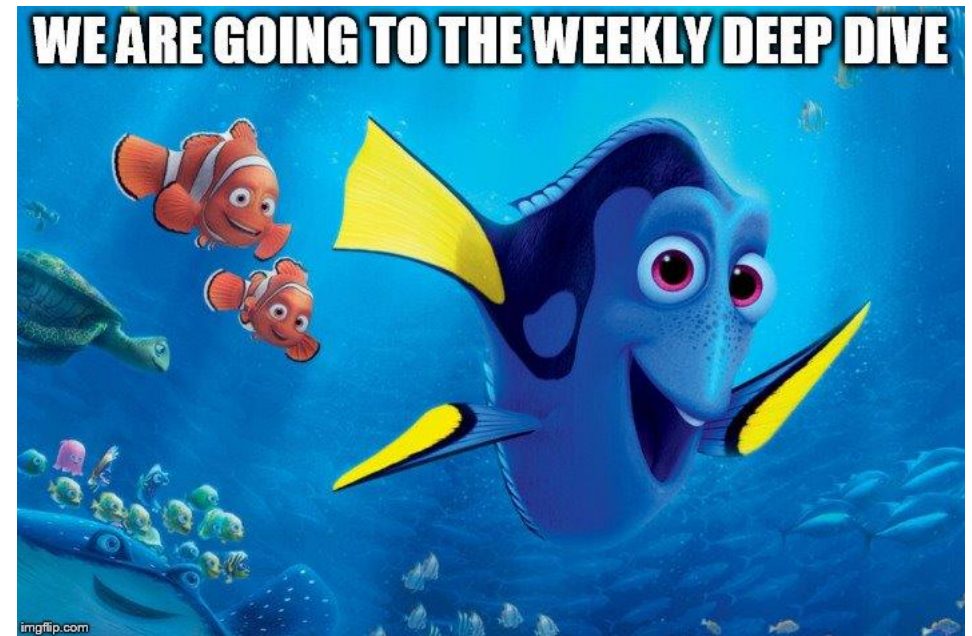MBBS(Hons), MMedSC(UWA),

PGCertMedEd(Cambridge), FRANZCO

21st March 2026

What we'll cover

- The Bidirectional Relationship
 - Glaucoma therapy can cause cataract
 - How cataract surgery can help glaucoma
- The role of MIGS
- How Cataract Surgery effects Trabeculectomy
- Surgical challenges
- IOL Selection



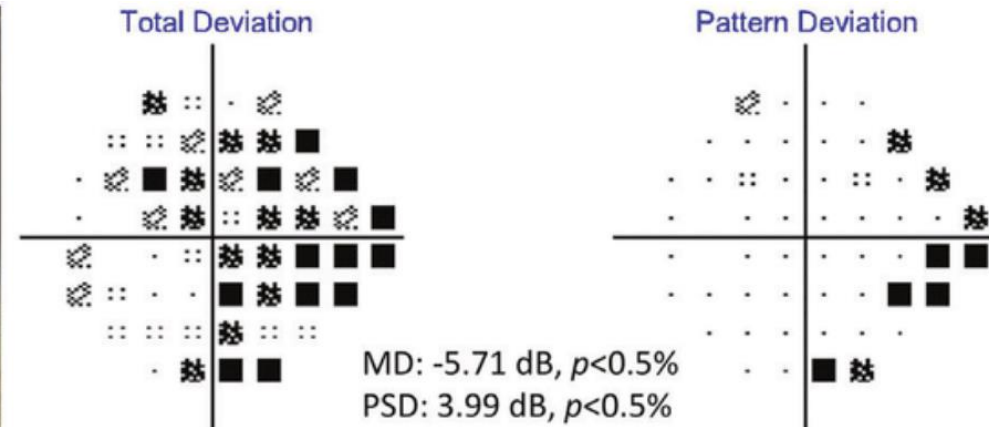
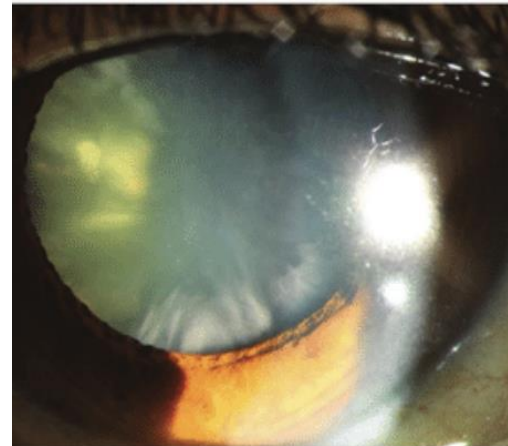
The Cataract-Glaucoma Relationship

Frequently coexist

- Both Age-Related
- Approximately 1 in 5 people undergoing cataract surgery have glaucoma or OHT

Clinical implications

- Cataract can make visual field interpretation difficult
- Surgical planning needs to achieve lower IOP with visual rehabilitation



Phu J, Khuu SK, Yapp M, Assaad N, Hennessy MP, Kalloniatis M. The value of visual field testing in the era of advanced imaging: clinical and psychophysical perspectives. Clin Exp Optom. 2017 Jul;100(4):313-332.

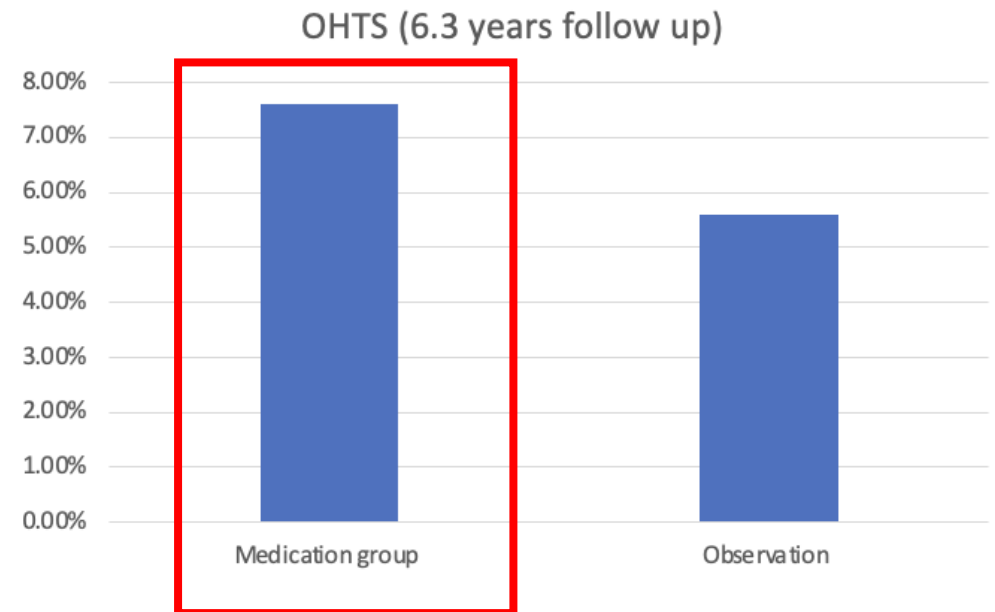
Glaucoma Treatment Accelerates Cataract

Medications

- Long-term drops → ocular surface disease and **inflammation**
- Topical **steroids** post glaucoma surgery

Laser

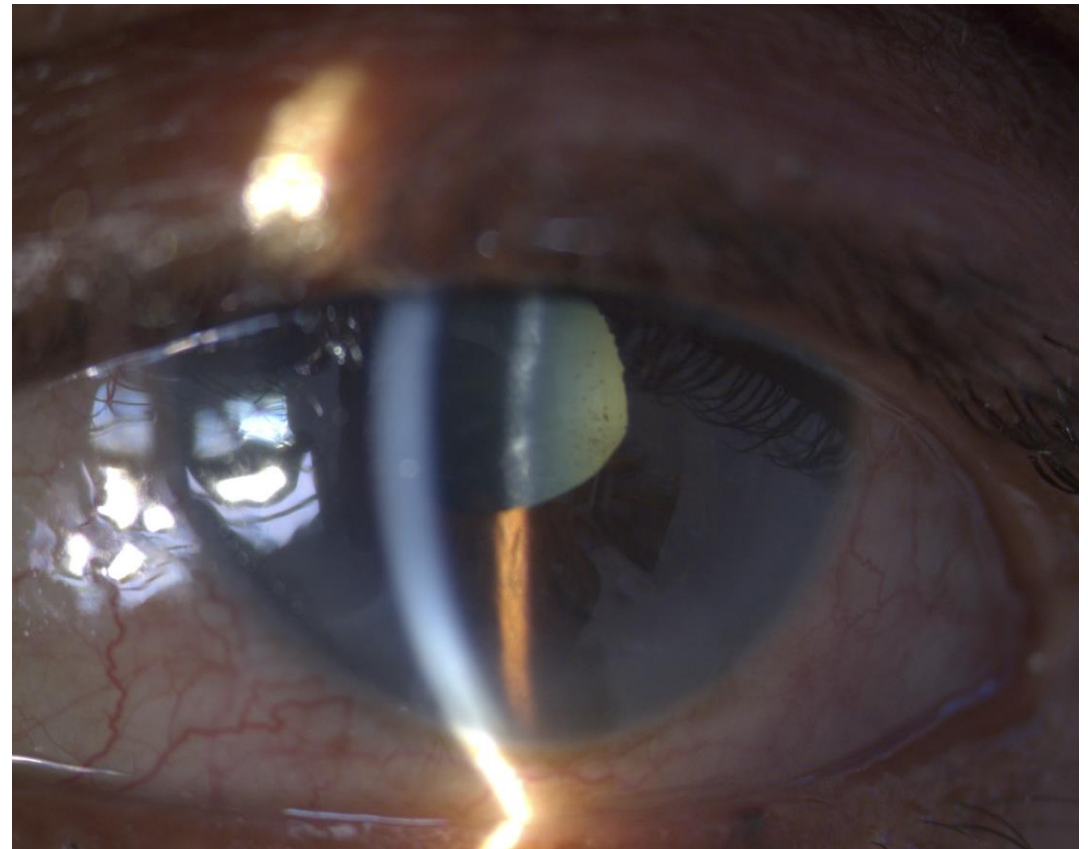
- Laser peripheral iridotomy may accelerate lens opacity in some patients



Cataract Worsens after Glaucoma Surgery

- Following glaucoma surgery, up to **~50% cataract surgery** by 5 years
- AGIS study- 78% increase in the risk post trabeculectomy of:
 - Developing cataract
 - Undergoing cataract surgery

Cataract progression is **common after filtration surgery**



Cataract surgery IS glaucoma surgery

[Int Ophthalmol Clin](#). Author manuscript; available in PMC 2019 Jul 1.

Published in final edited form as:

[Int Ophthalmol Clin](#). 2018 Summer; 58(3): 87-100.

doi: [10.1097/IIO.0000000000000234](https://doi.org/10.1097/IIO.0000000000000234)

PMCID: PMC5992498

NIHMSID: NIHMS957654

PMID: [29870412](https://pubmed.ncbi.nlm.nih.gov/29870412/)



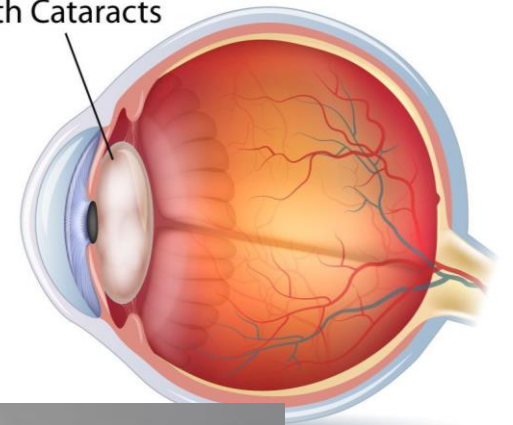
RESOURCES

[Similar articles](#) +

[Cited by other articles](#) +

[Links to NCBI Databases](#) +

Lens With Cataracts



Role of Cataract Surgery in the Management of Glaucoma

Jeanie D. Ling, MD^{1,2} and Nicholas P. Bell, MD^{1,2}

[▶ Author information](#) [▶ Copyright and License information](#) [▶ PMC Disclaimer](#)

The publisher's final edited version of this article is available at [Int Ophthalmol Clin](#)

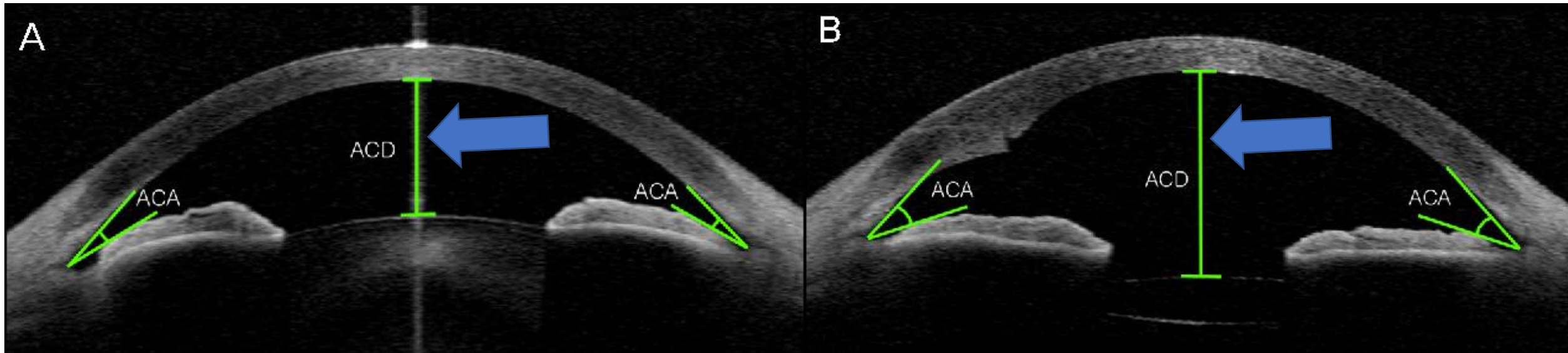
Abstract

[Go to: ▶](#)

A leading cause of blindness, glaucoma is estimated to affect 60.5 million people worldwide, with a projected increase to 79.6 million by 2020. Cataract surgery is the most commonly performed ophthalmic surgery, with the anticipated number of people requiring cataract surgery worldwide expected to rise to 30.1 million by the year 2020, a 50% increase from 2000. Cataract and glaucoma are both more prevalent among the elderly population and commonly coexist. This review will discuss the effect of cataract surgery on glaucoma treatment in various patient populations.



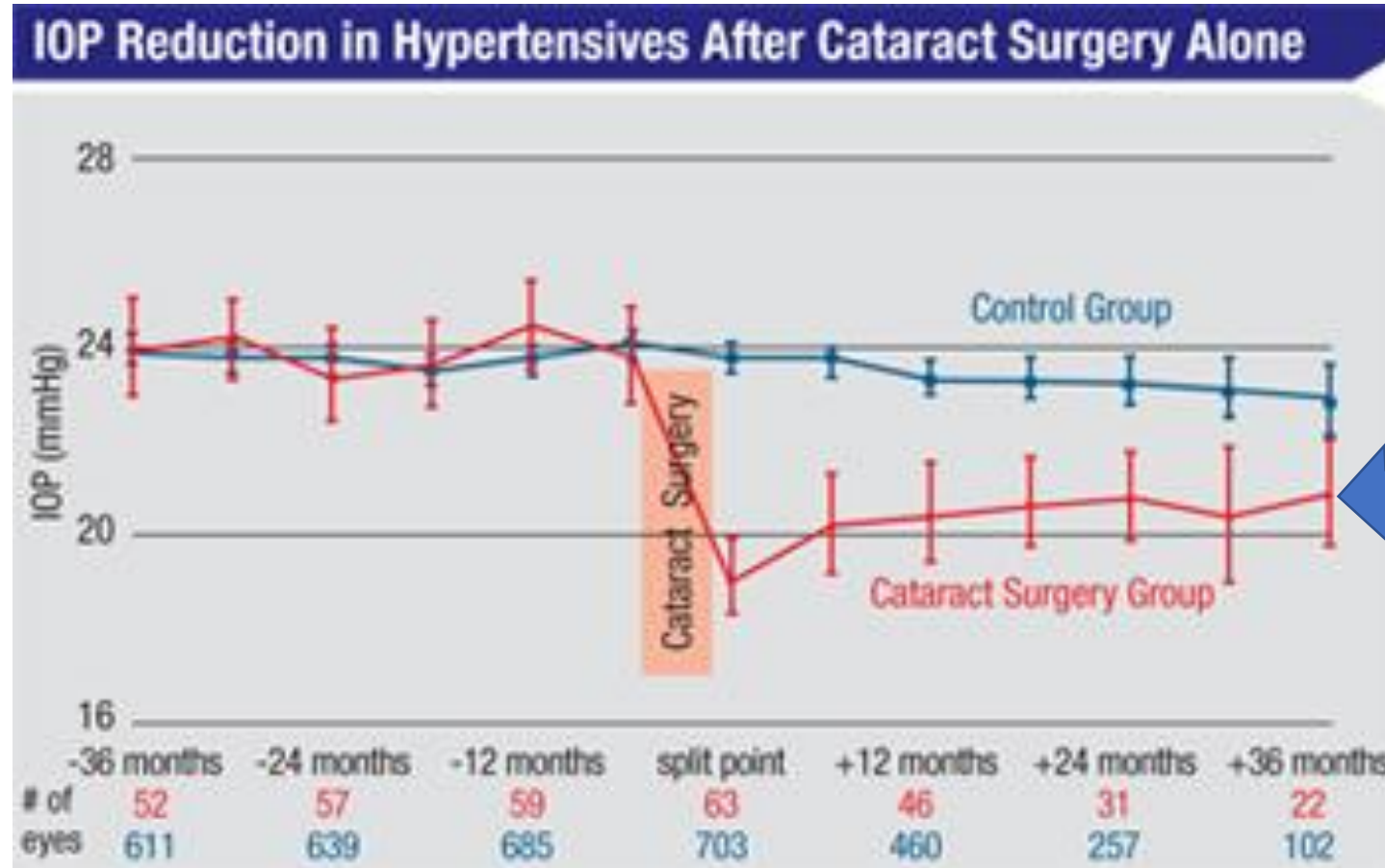
How does cataract surgery help glaucoma?



- Increased **lens vault**
- Reduced **angle opening distance**
- Greater **pupillary block potential**

- Deepen the anterior chamber
- Widen the angle
- Reduce trabecular compression
- Increase Schlemm canal patency
- Enhance conventional outflow facility

OHTS showed average of 16.5% (4mmHg) reduction in the cataract surgery group



(Adapted from Mansberger, et al.)

Cataract Surgery- Postoperative pressure spikes

- Incidence
 - 5.2% of eyes with glaucoma experience a significant IOP spike
 - Early IOP spikes can occur within the first 24–48 hours
- Monitor IOP closely
- Adjust glaucoma therapy if needed



Cataract Surgery...An Opportunity for Trabecular MicroBypass



MBS Online
Medicare Benefits Schedule

Category 3 - THERAPEUTIC PROCEDURES

42705 

Group T8 - Surgical Operations

Subgroup 9 - Ophthalmology

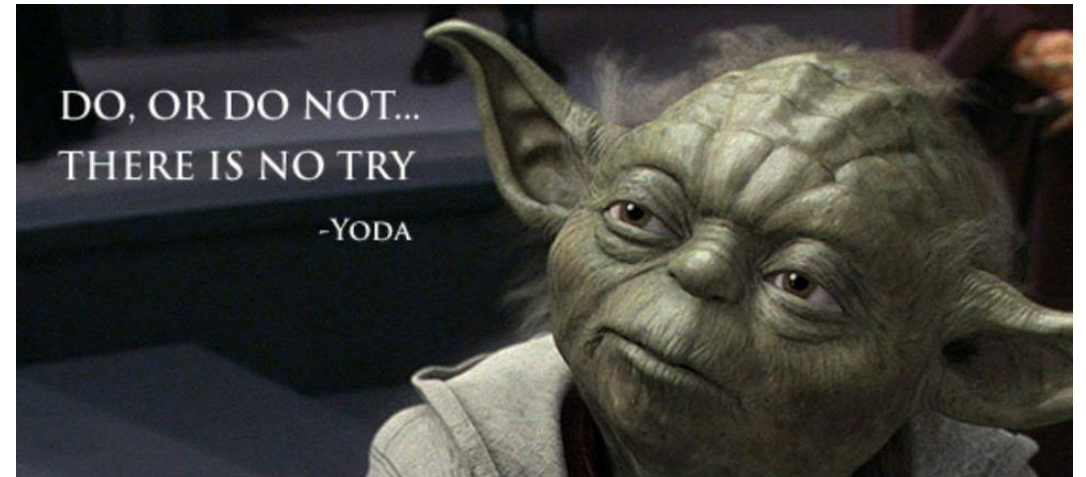
Lens extraction and insertion of intraocular lens, excluding surgery performed for the correction of refractive error except for anisometropia greater than 3 dioptries following the removal of cataract in the first eye, performed in association with insertion of a micro-bypass glaucoma surgery device or devices into the suprachoroidal space or trabecular meshwork, in a patient diagnosed with open angle glaucoma who is not adequately responsive to topical anti-glaucoma medications or who is intolerant of anti-glaucoma medication (H)

[Multiple Operation Rule](#)

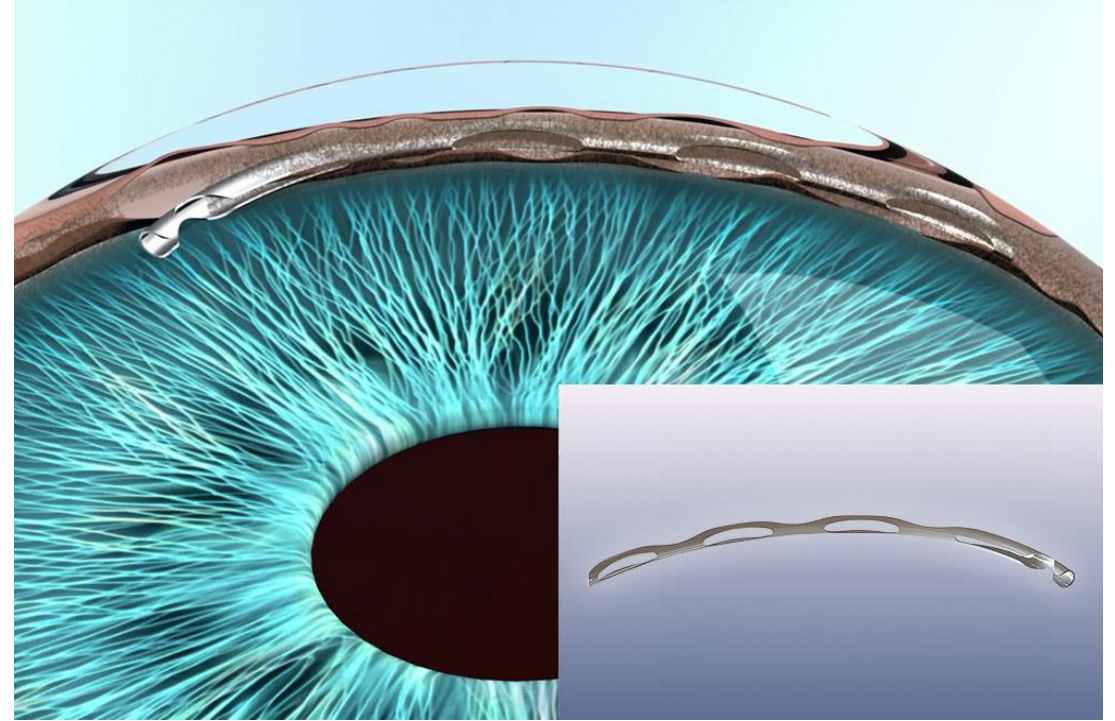
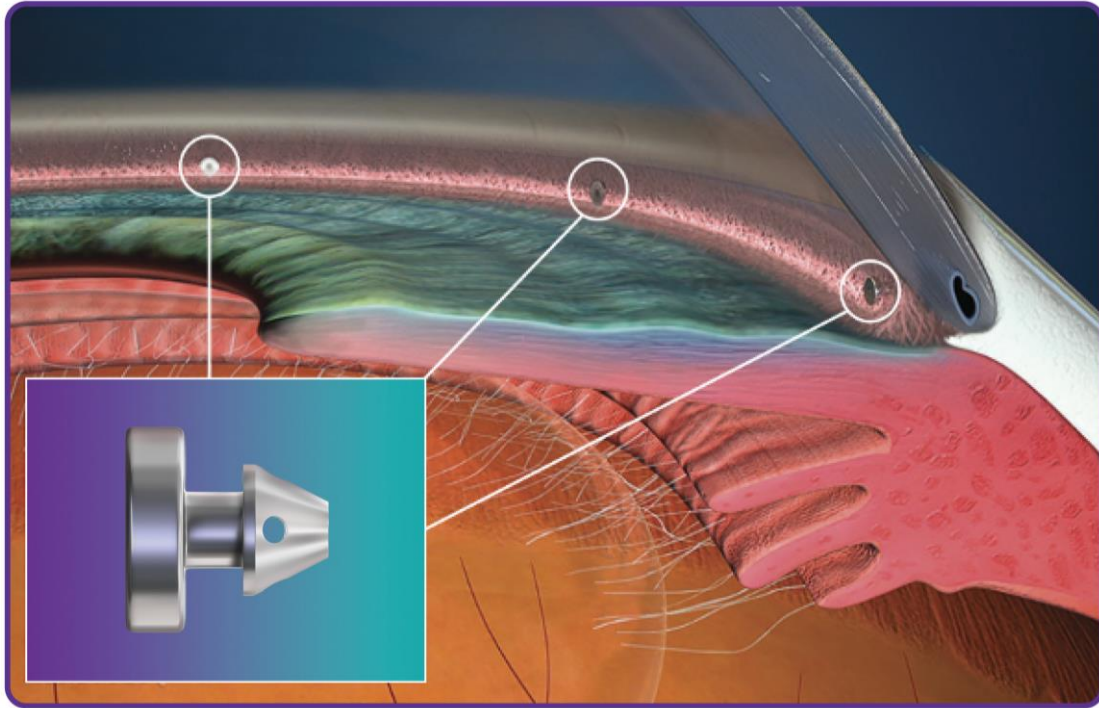
To MIGS or not to MIGS

Appropriate candidates

- Mild to moderate glaucoma
- Additional IOP reduction is desired
- Patients requiring reduction in glaucoma medications
- Patients with medication intolerance or adherence issues



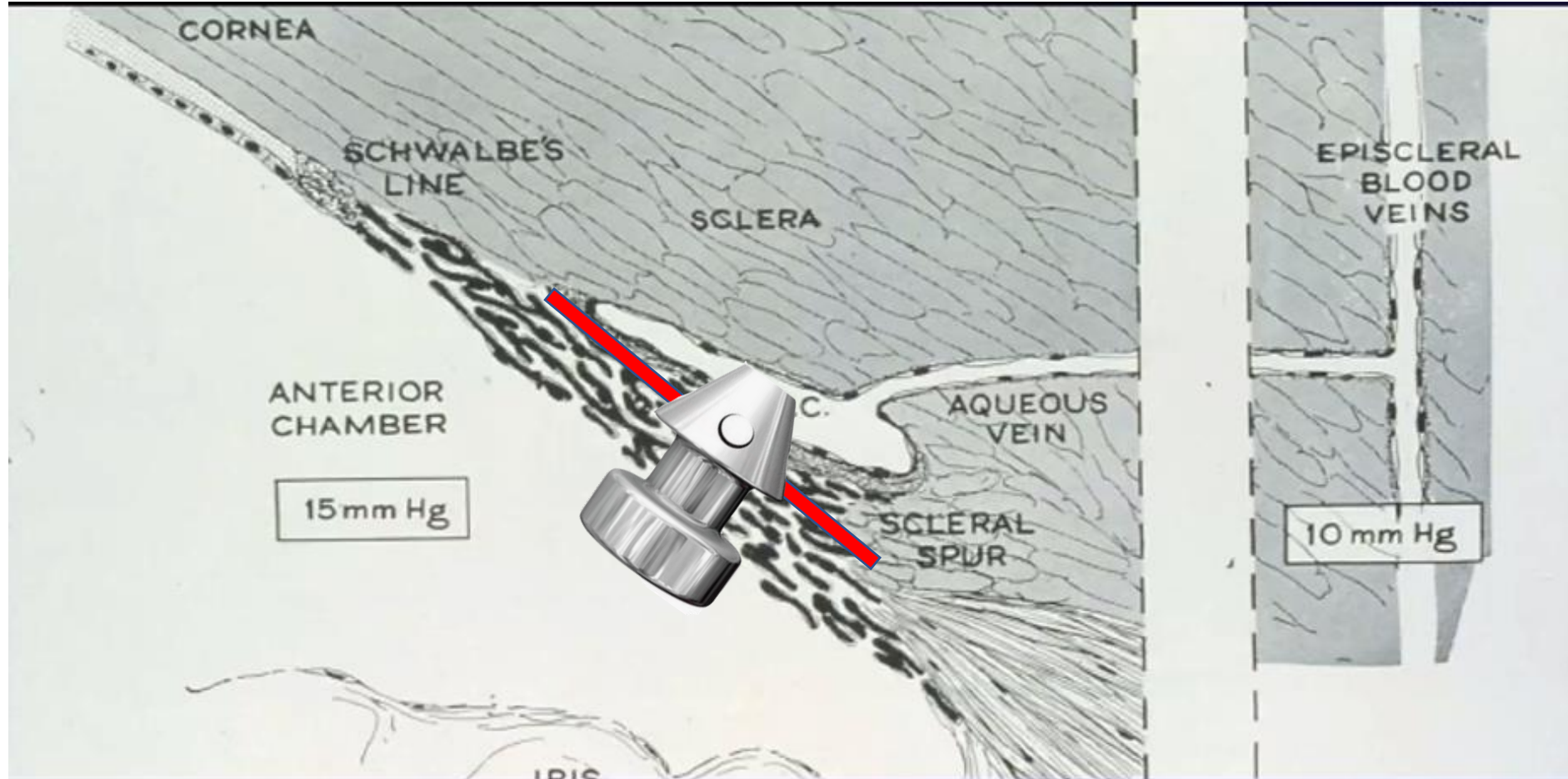
Stent Design and Features



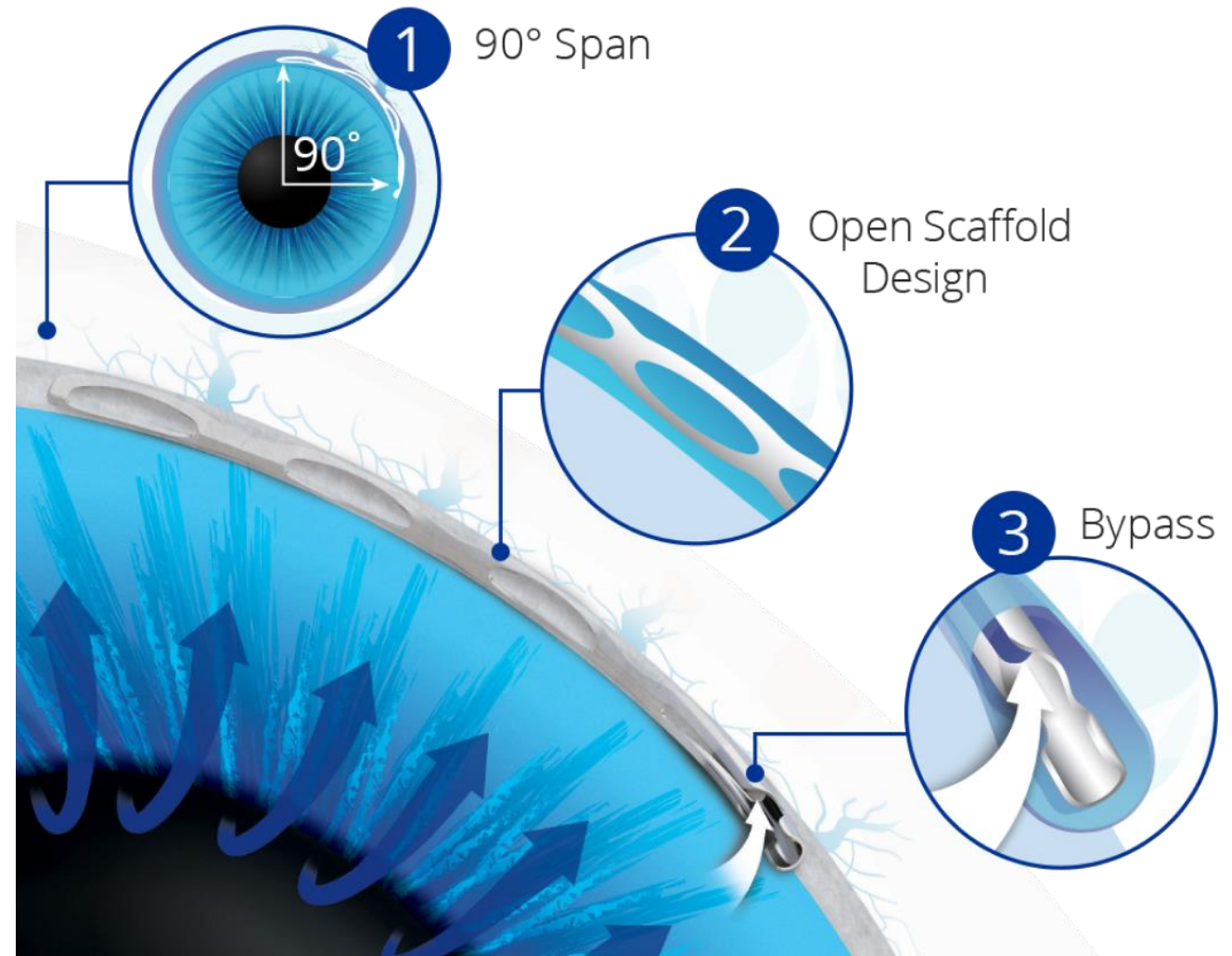
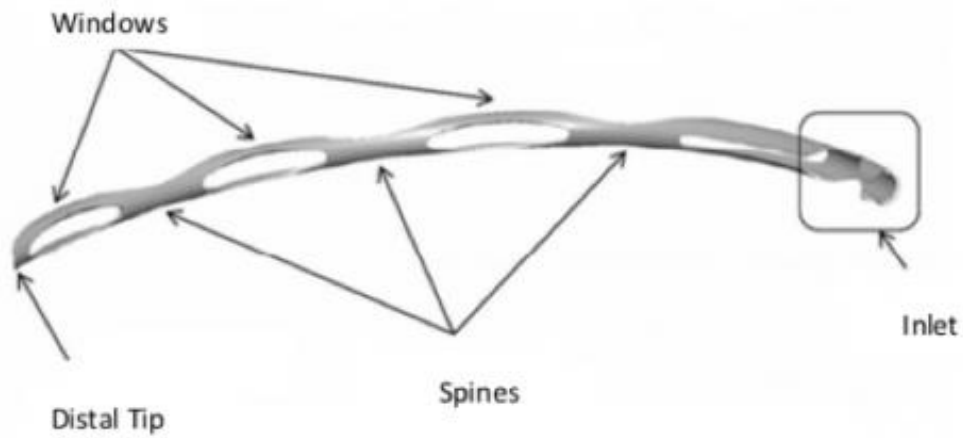
iStent
infinite...

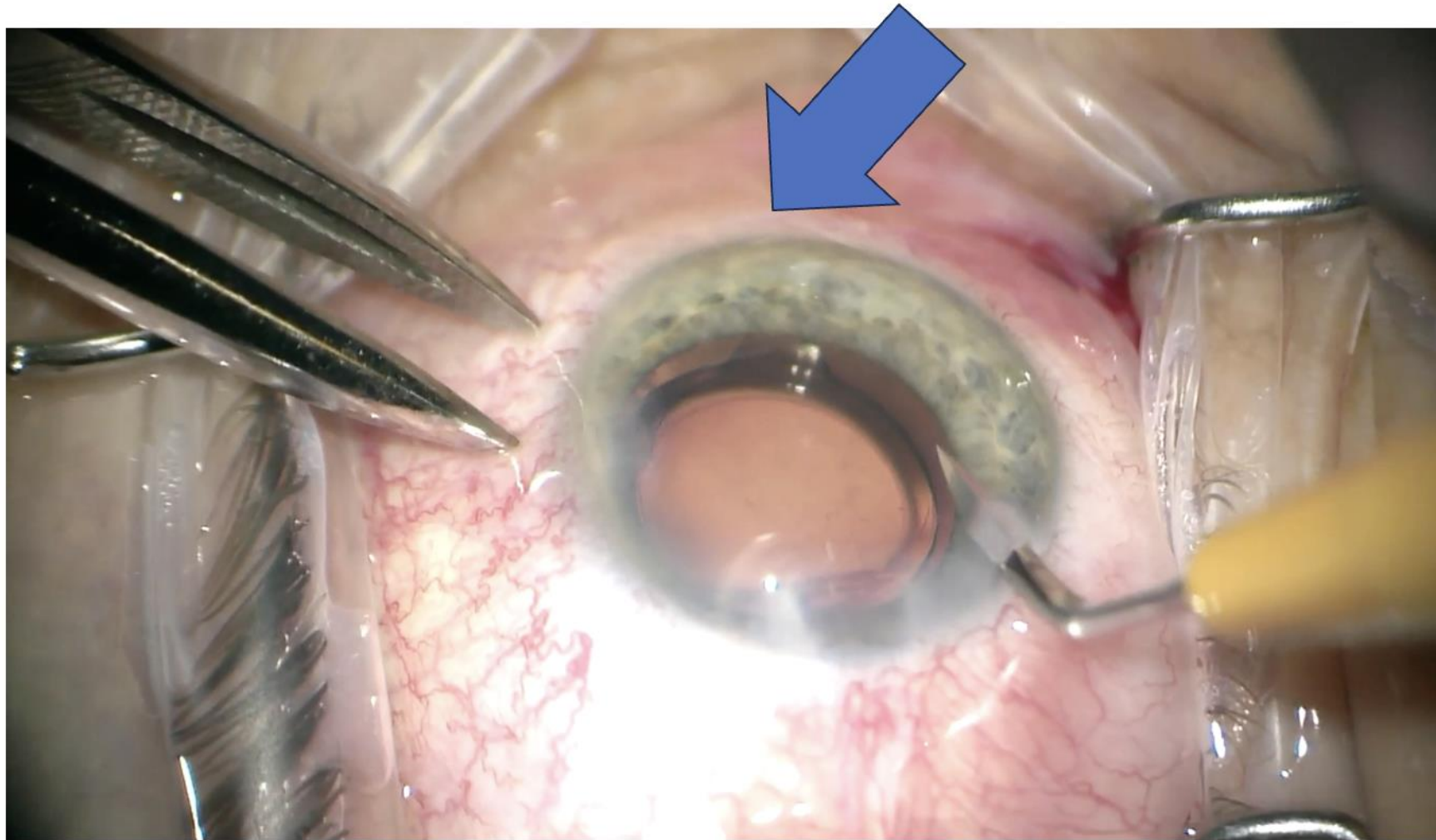
HYDRUS[®]
MICROSTENT


HOW does it work?



Hydrus Microstent



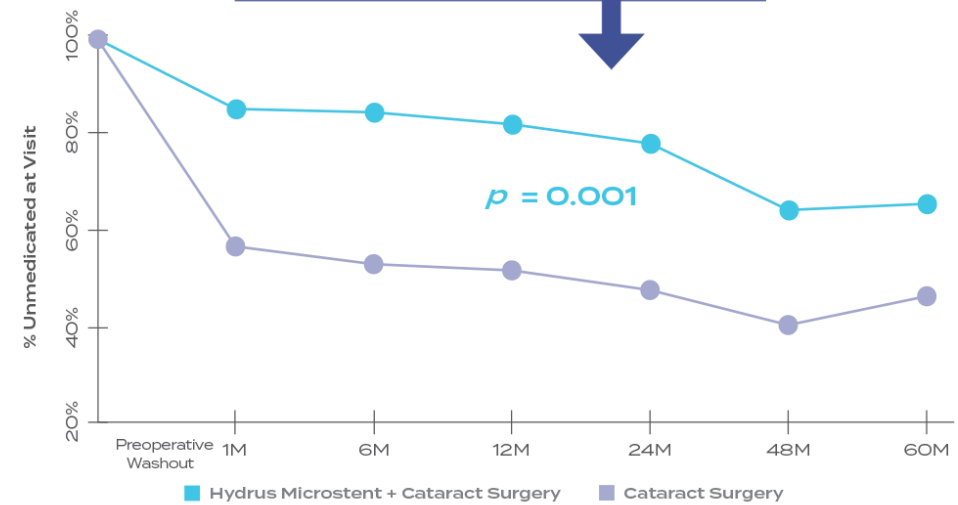




% of Medication-Free Patients

66%

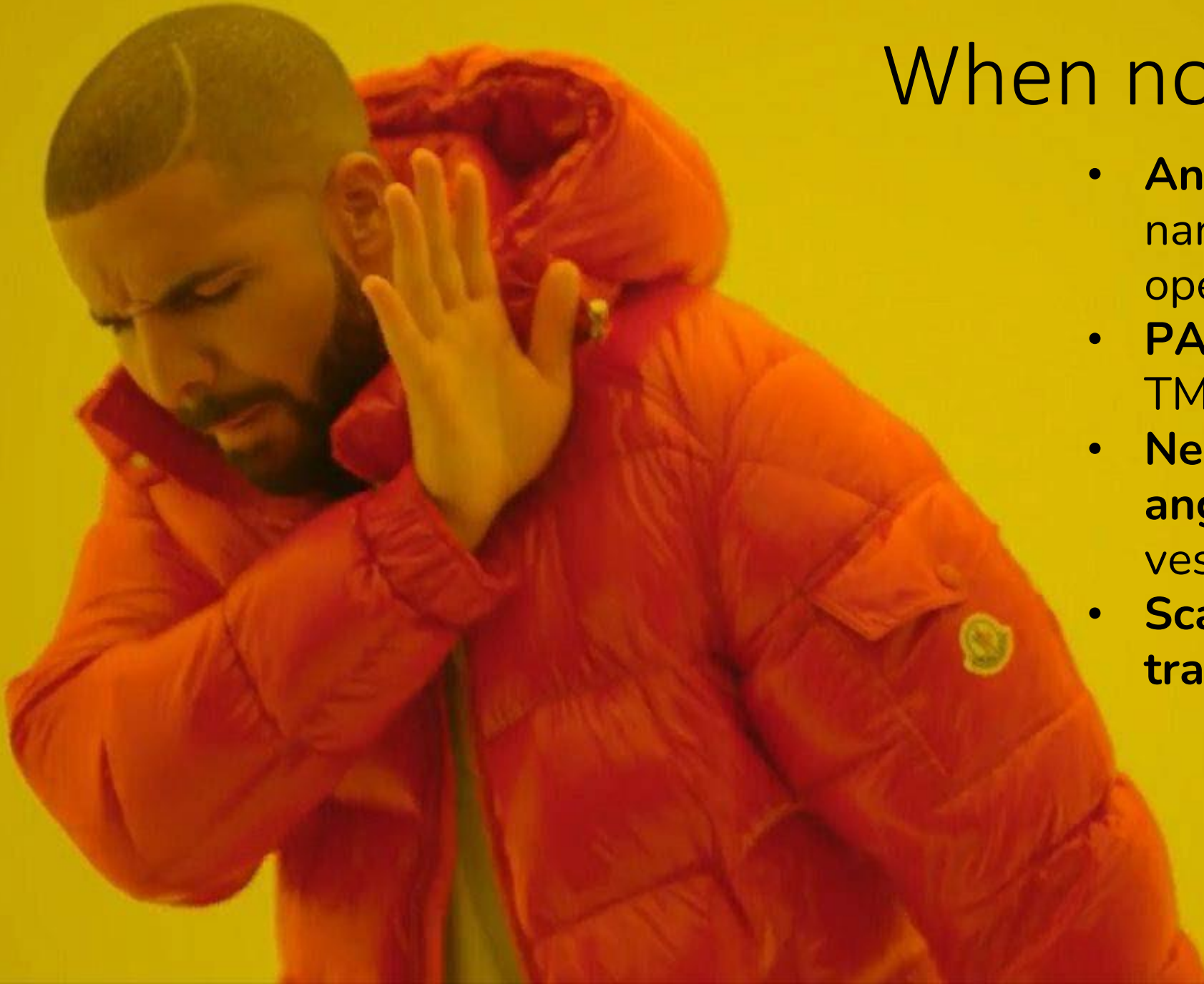of Hydrus Microstent patients remained medication-free at 5 years¹



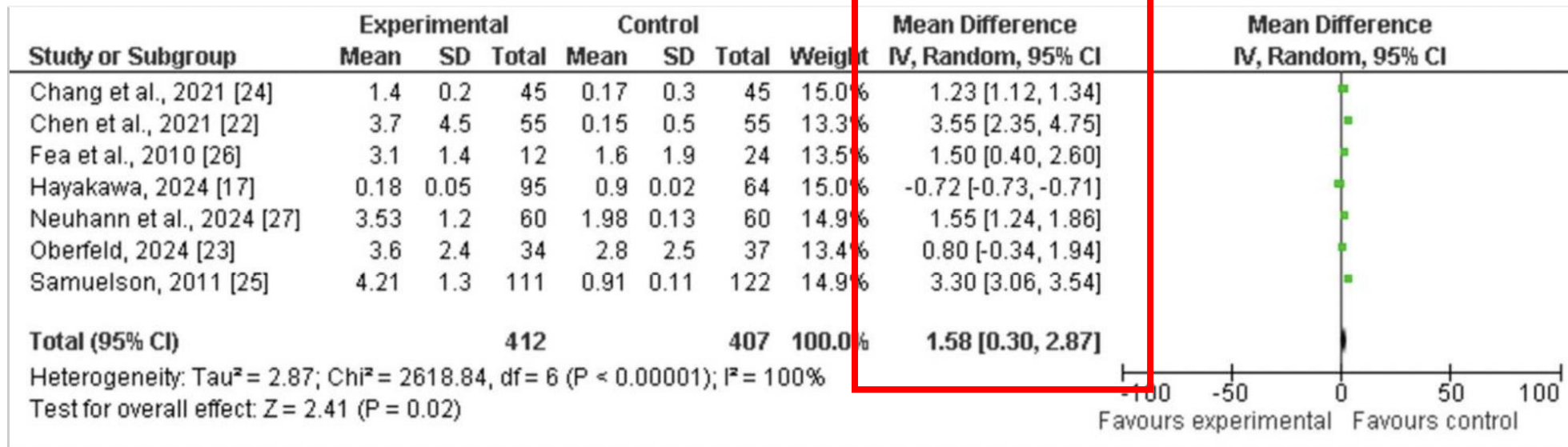
20-30% margin over 5 year follow up

When not to MIGS

- **Angle closure:**
narrow/closed angle unless opened surgically
- **PAS:** blocks access to TM/SC
- **Neovascularisation of angle (NVG):** fragile vessels, bleeding risk
- **Scarred angle from prior trab/tube surgery**



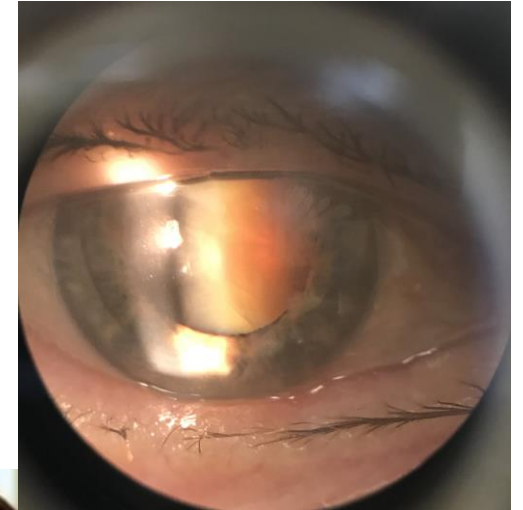
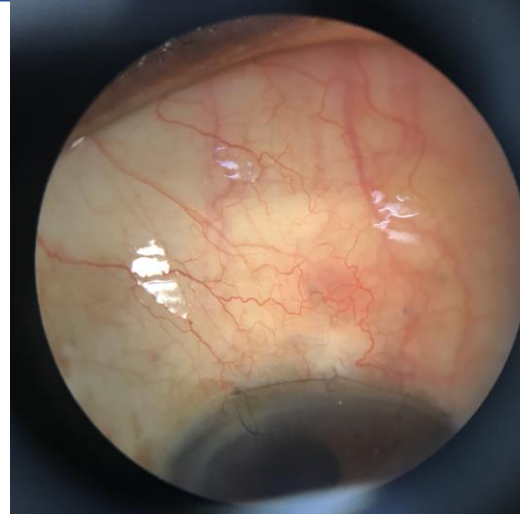Outcomes of Minimally Invasive Glaucoma Surgery (MIGS) in Glaucoma Patients With Coexisting Cataract



- **Meta-analysis of 7 studies (669 eyes)** evaluating MIGS in glaucoma patients with coexisting cataract (2010–2024).
- **Significant reduction in IOP** compared with controls (mean difference **-1.58 mmHg**).
- **Reduced postoperative medication burden** (mean difference **-0.79 medications**), suggesting improved long-term management.

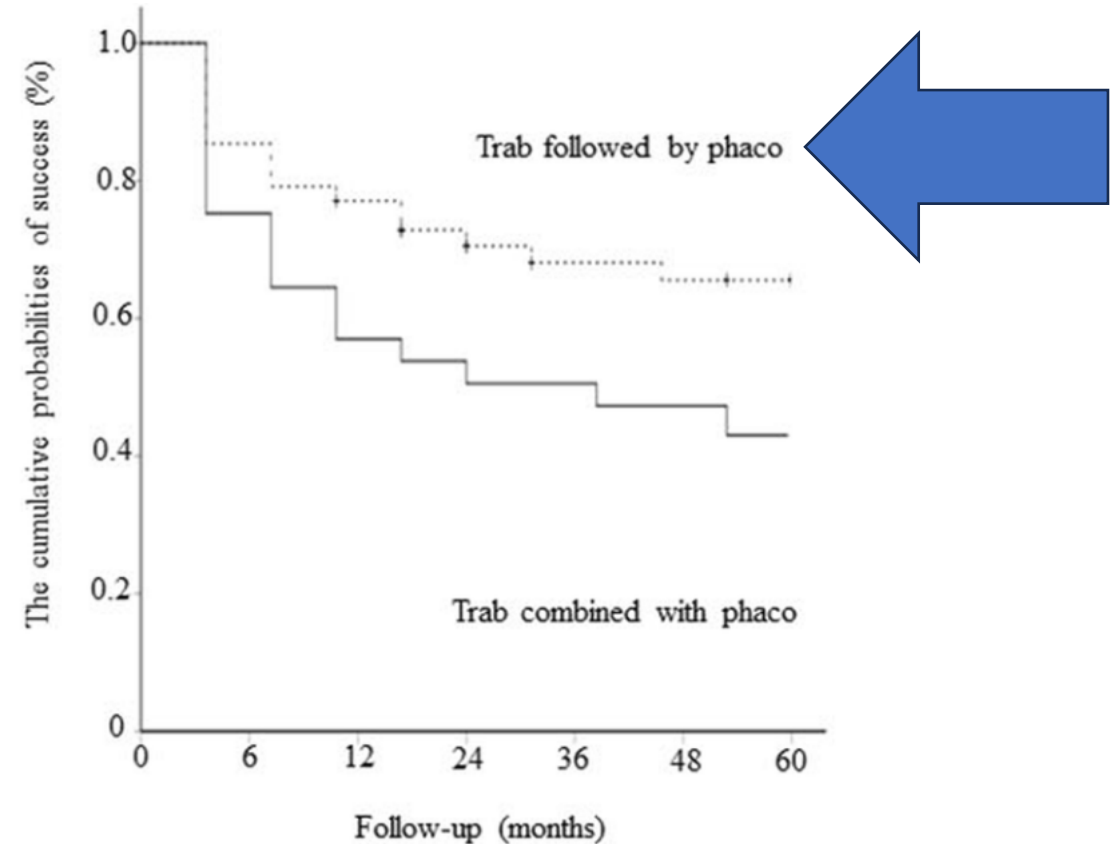
Combined cataract and Trabeculectomy

- Considered if cataract surgery alone may not adequately control IOP
 - Poorly controlled glaucoma
 - Advanced visual field loss
- Patient factors favour a single operation
- Economic or medication considerations



Disadvantages of Combined Phaco-Trab

- Lower long-term IOP control and better IOP reduction with doing glaucoma surgery alone
- Higher likelihood of requiring additional glaucoma medications
- Increased postoperative inflammation and scarring
- May lead to earlier bleb failure



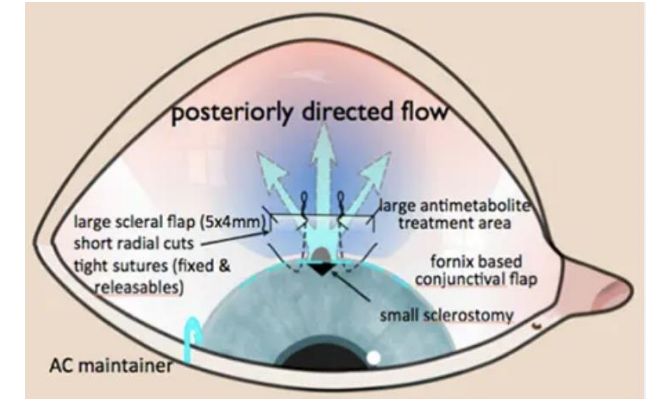
Zhang ML, Hirunyachote P, Jampel H. Combined surgery versus cataract surgery alone for eyes with cataract and glaucoma. Cochrane Database Syst Rev. 2015 Jul 14;2015(7).

Trabeculectomy Failure after Cataract Surgery

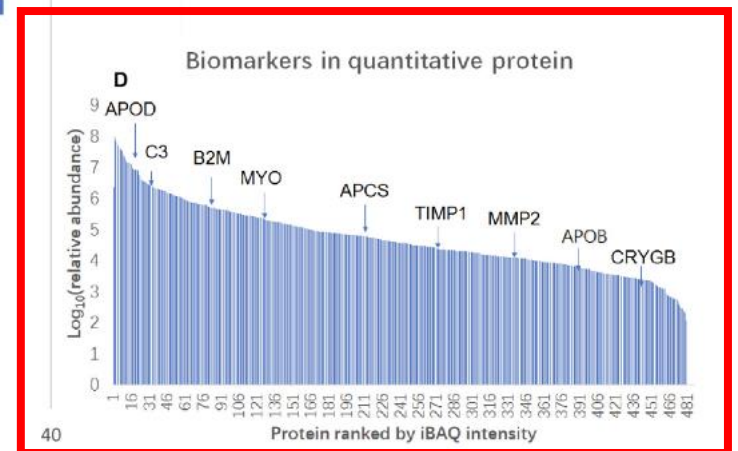
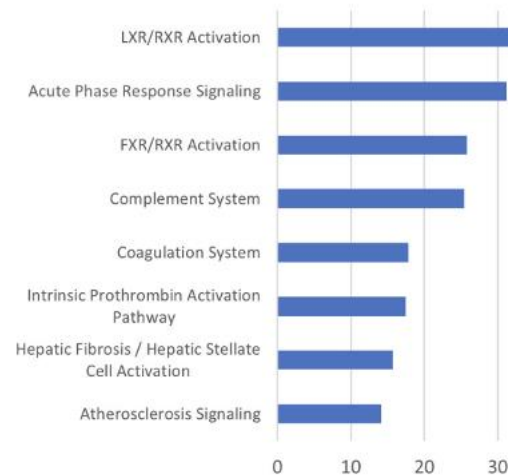
- Cataract surgery can compromise functioning filtering blebs
 - Especially high risk if <12 months

2 years after cataract surgery:

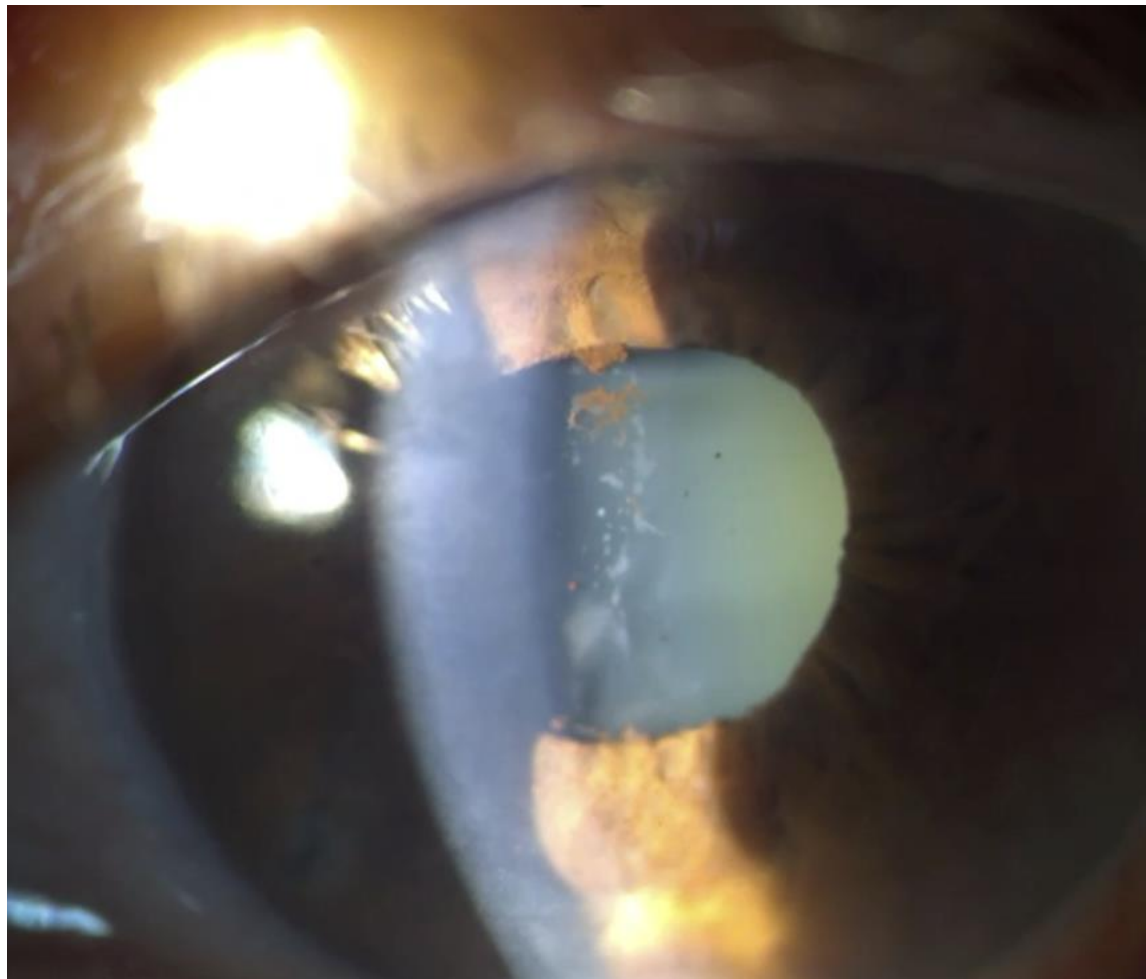
- ~10–35% bleb failure
- 18% additional glaucoma medications



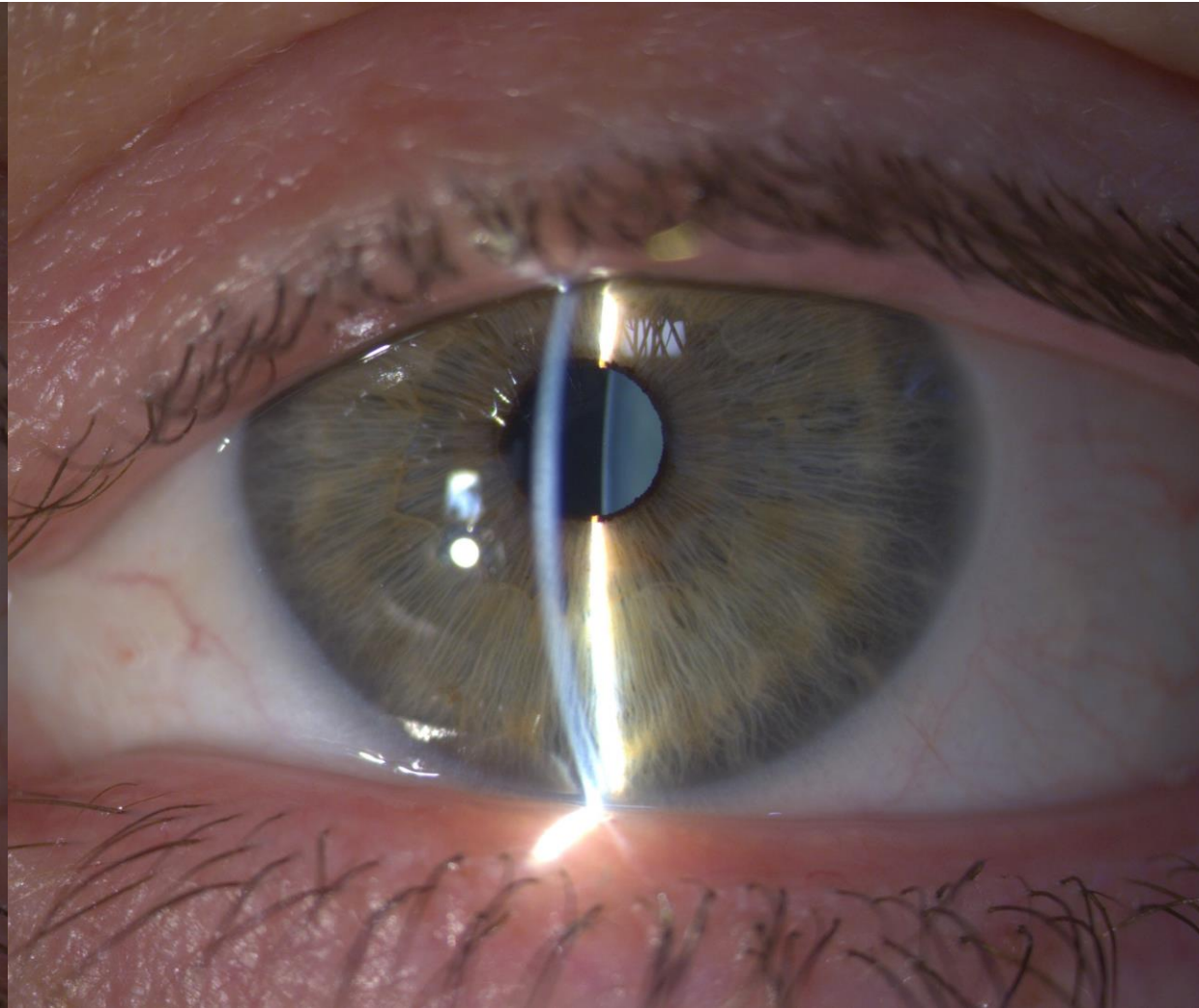
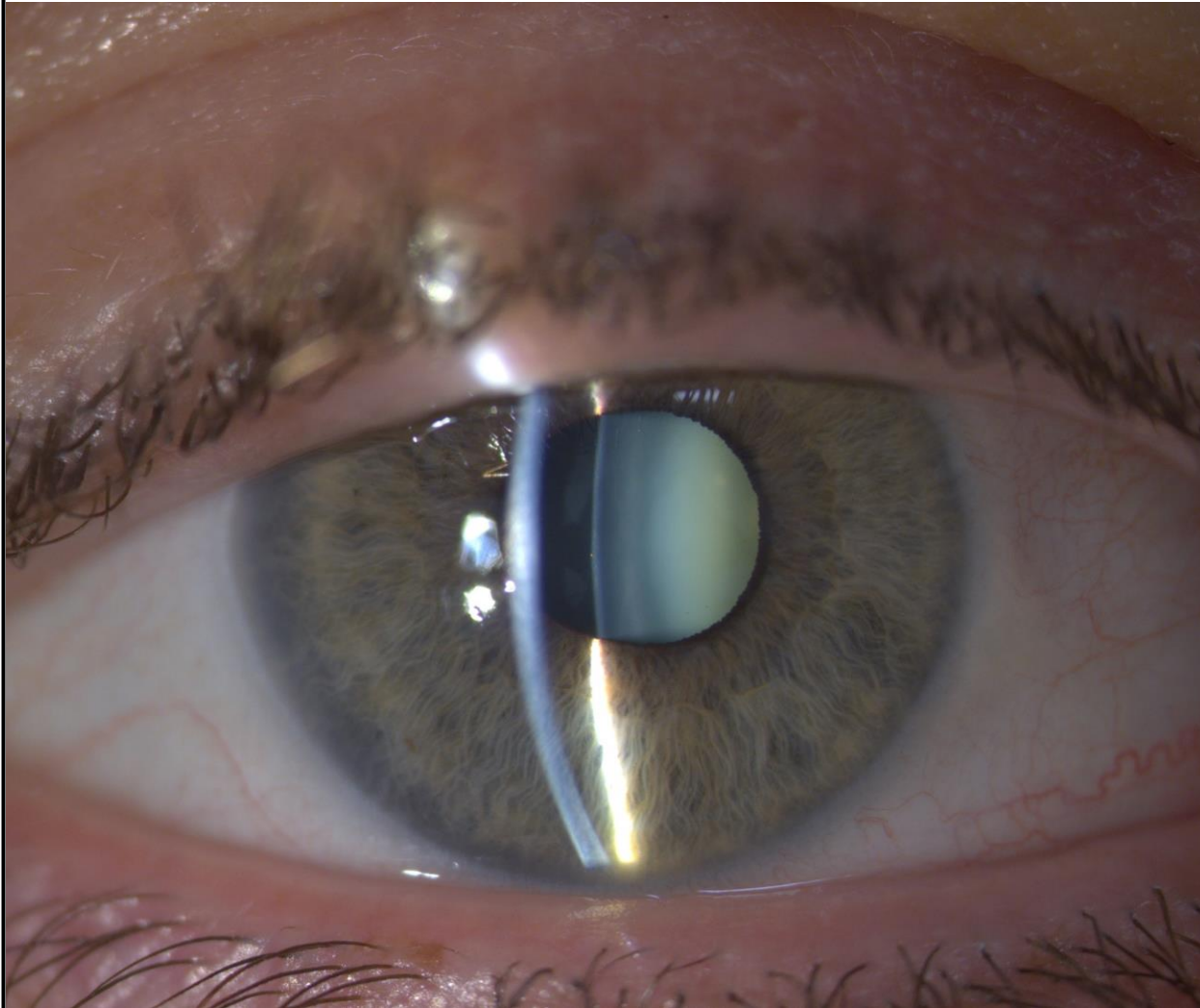
AH proteins-canonical pathways

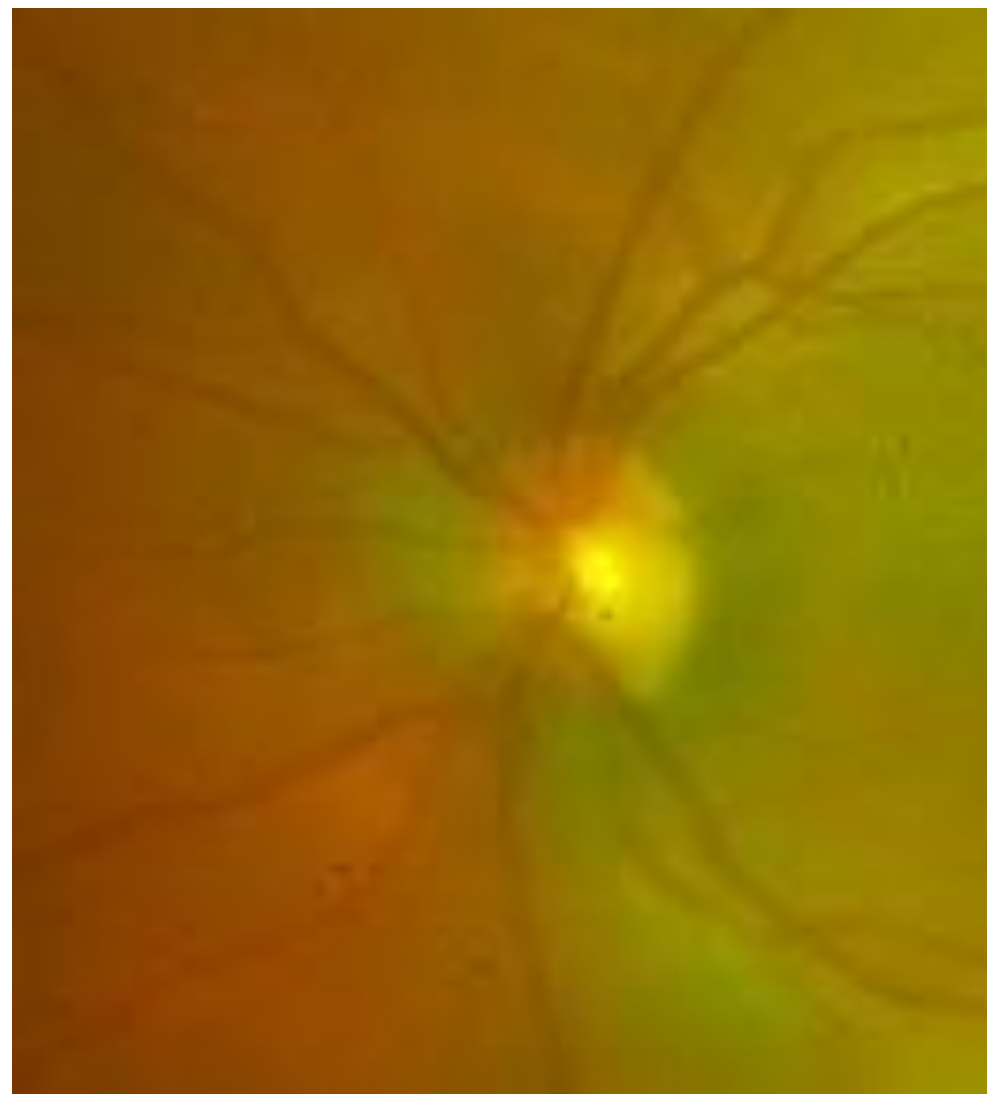
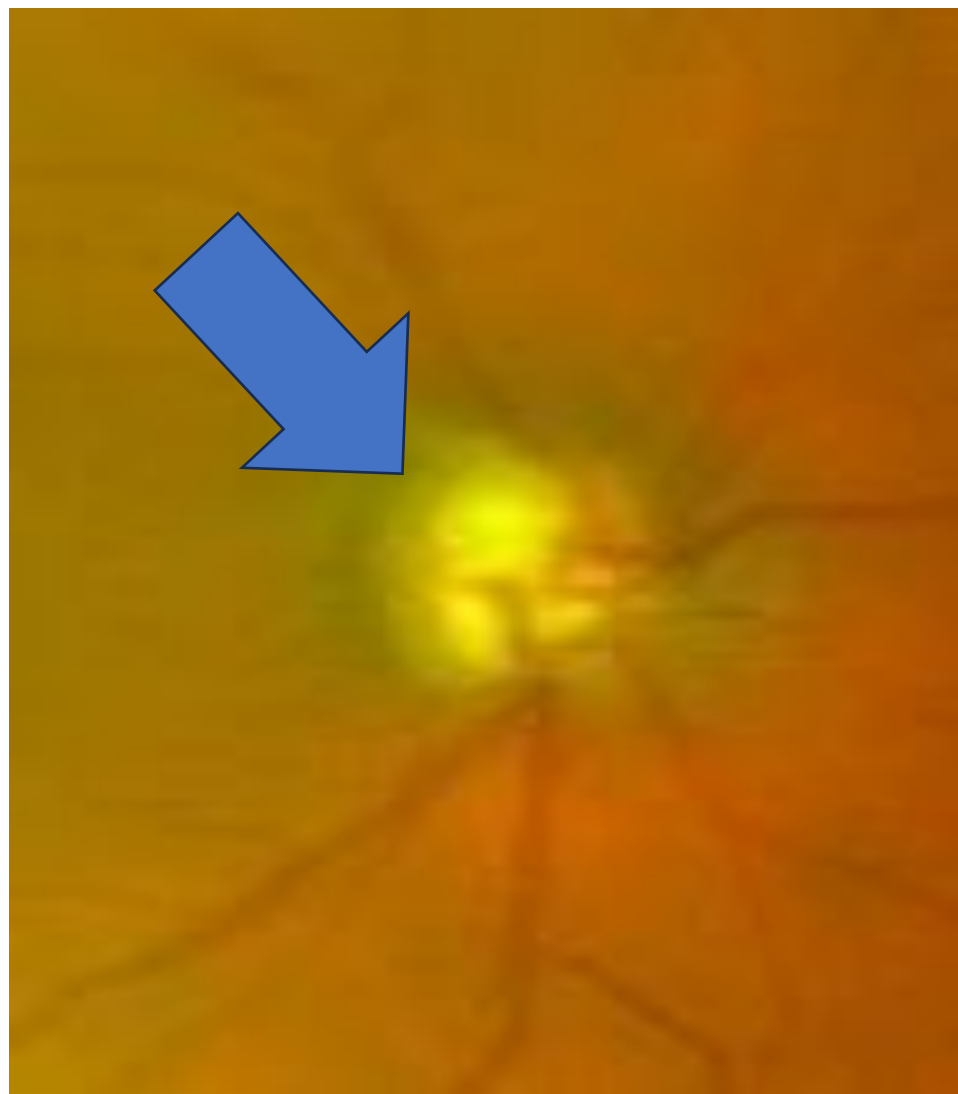

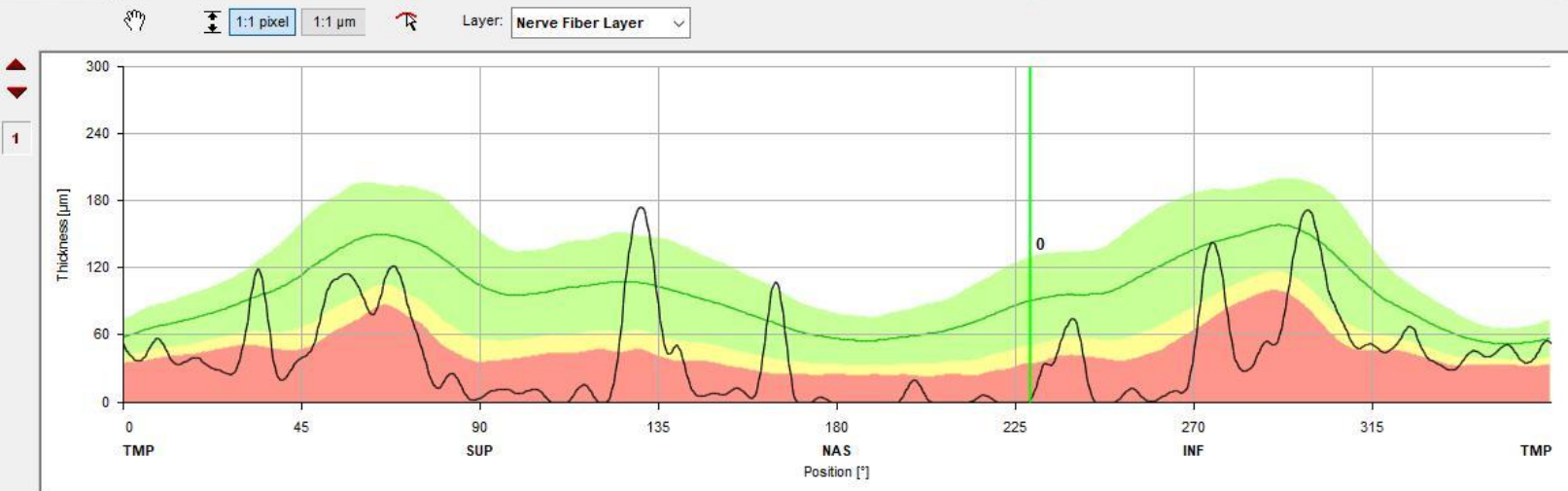
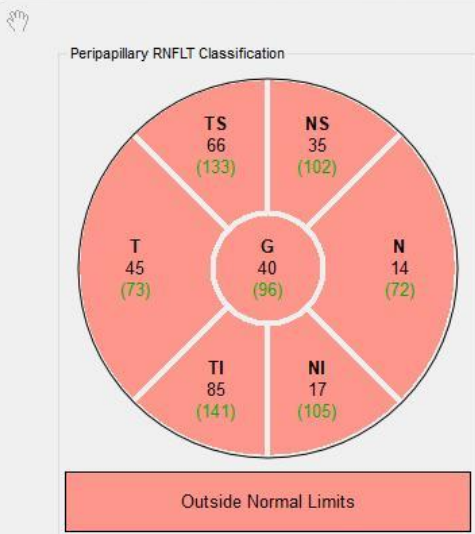
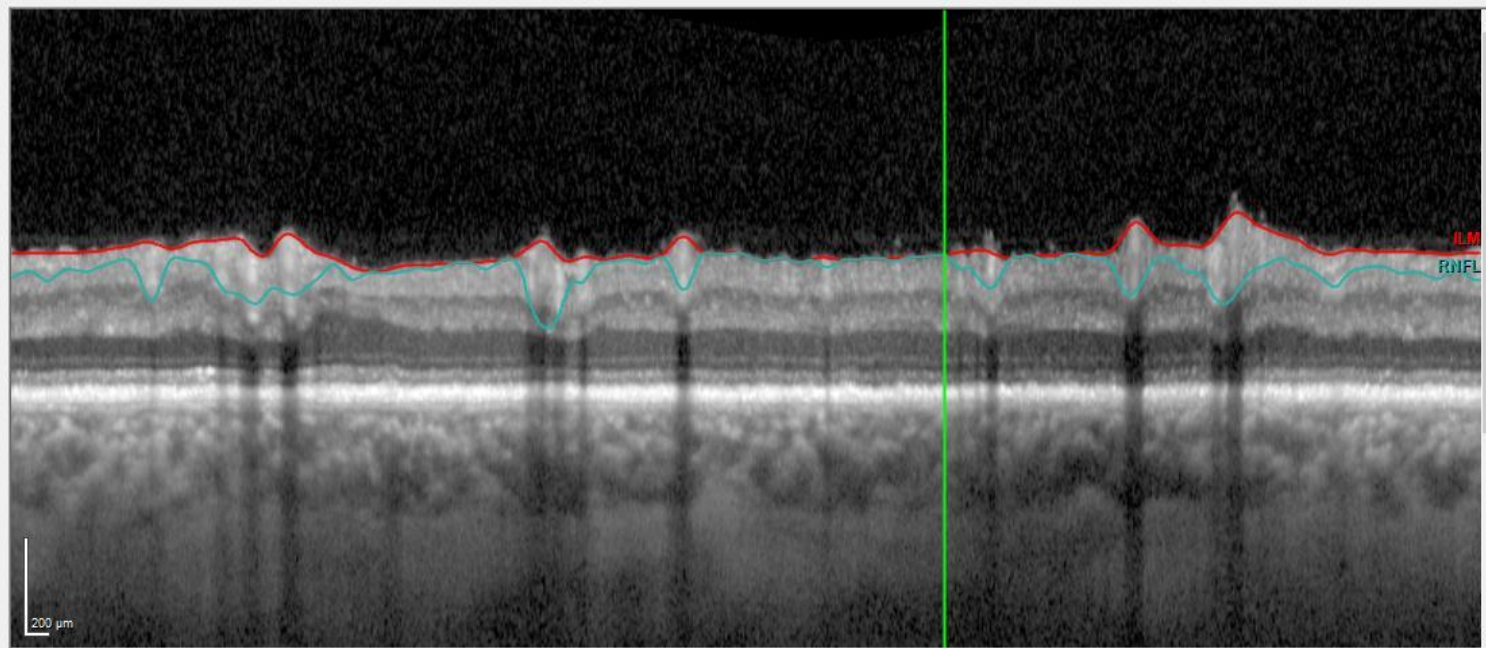
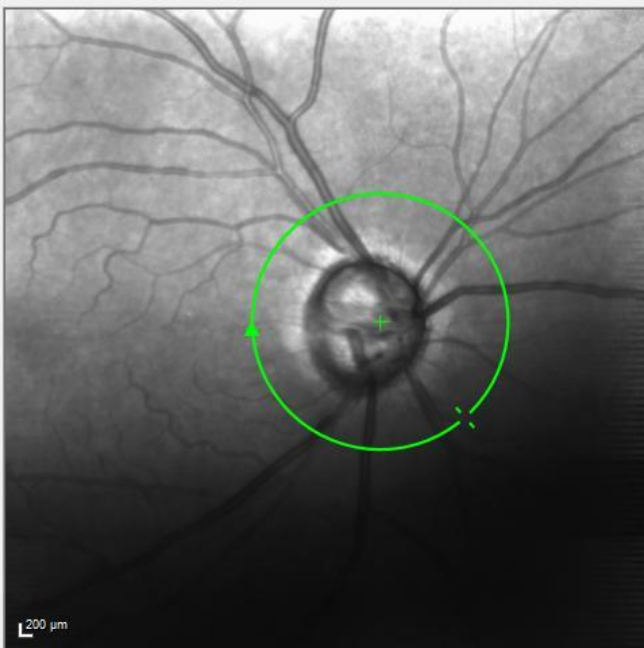
What About Angle Closure Eyes?

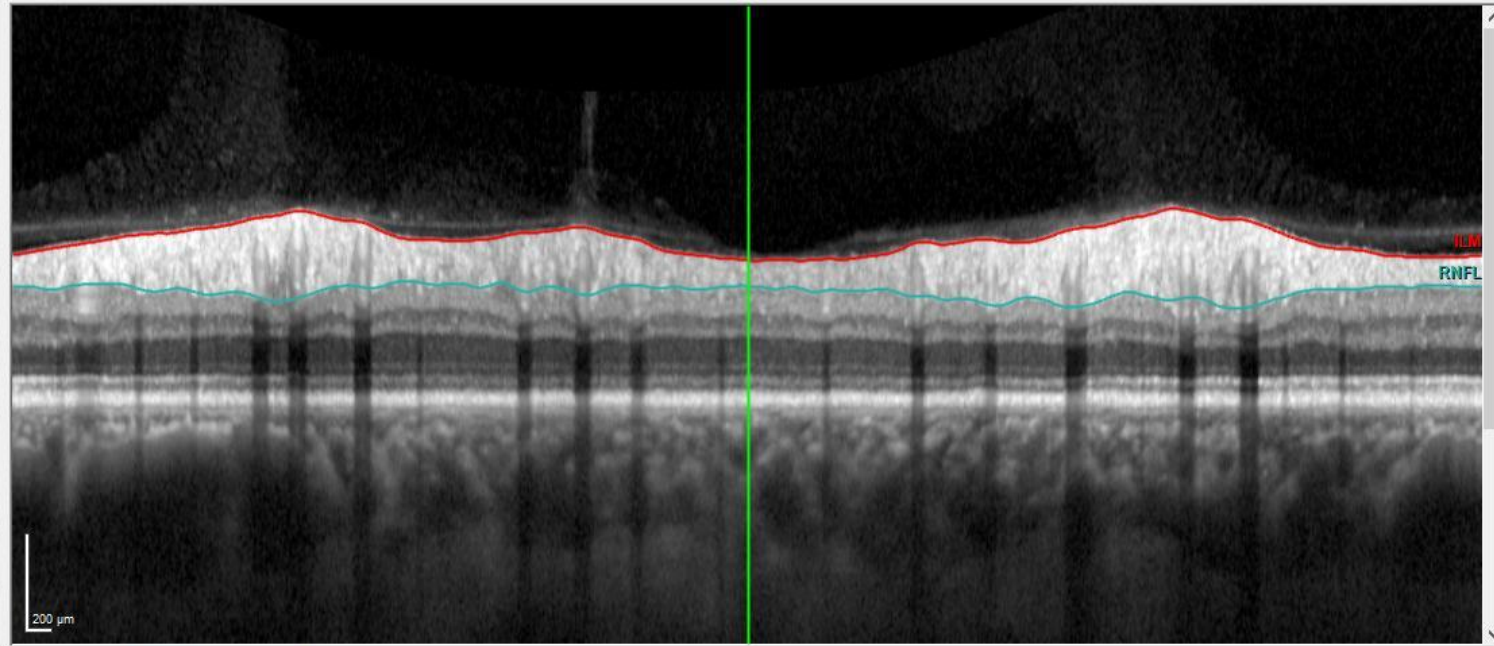
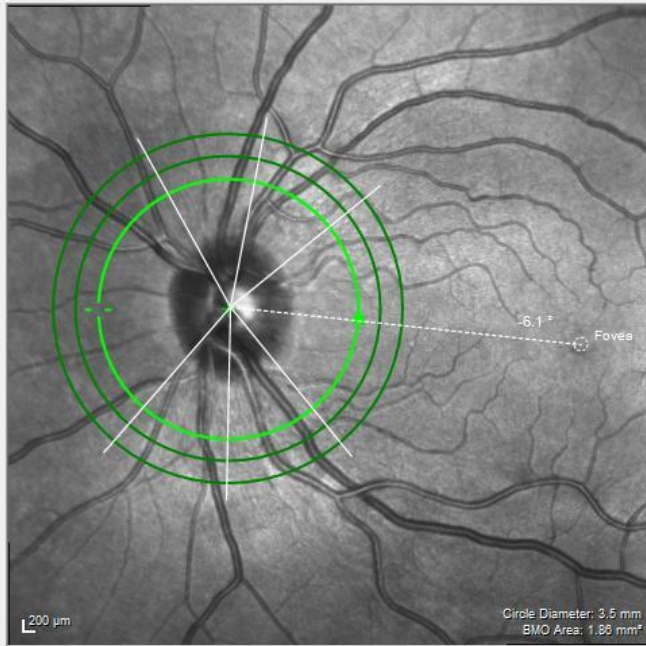


50 yo female with right vision loss. IOP 32/22



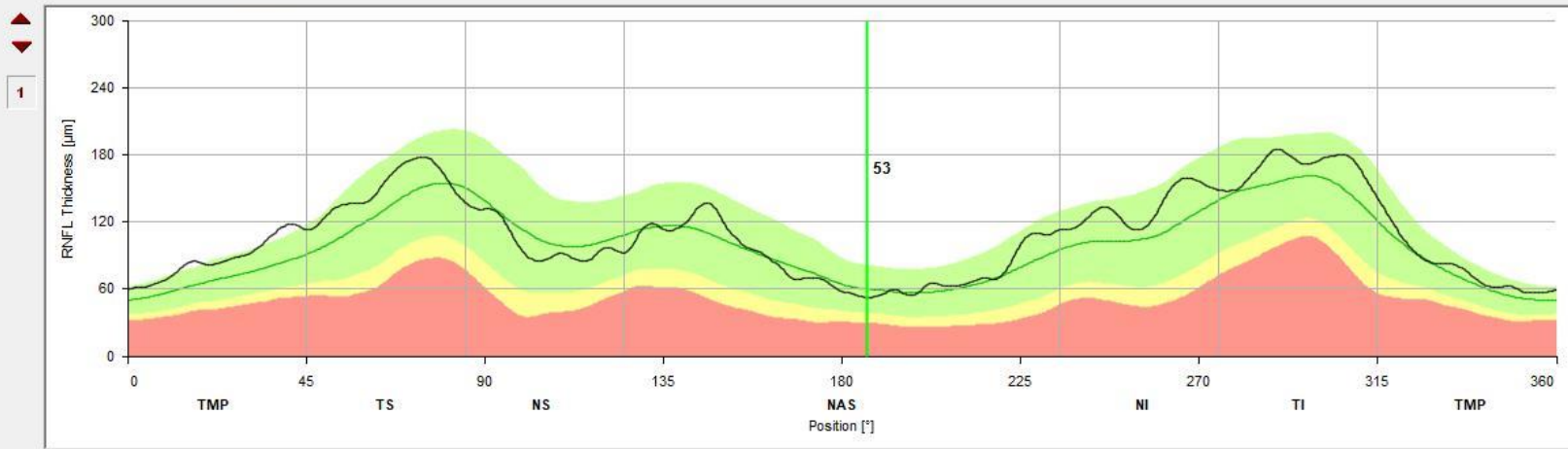
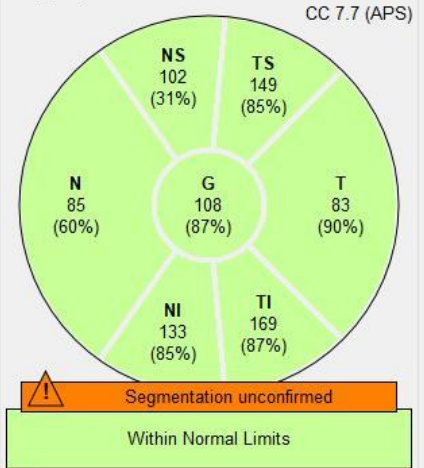




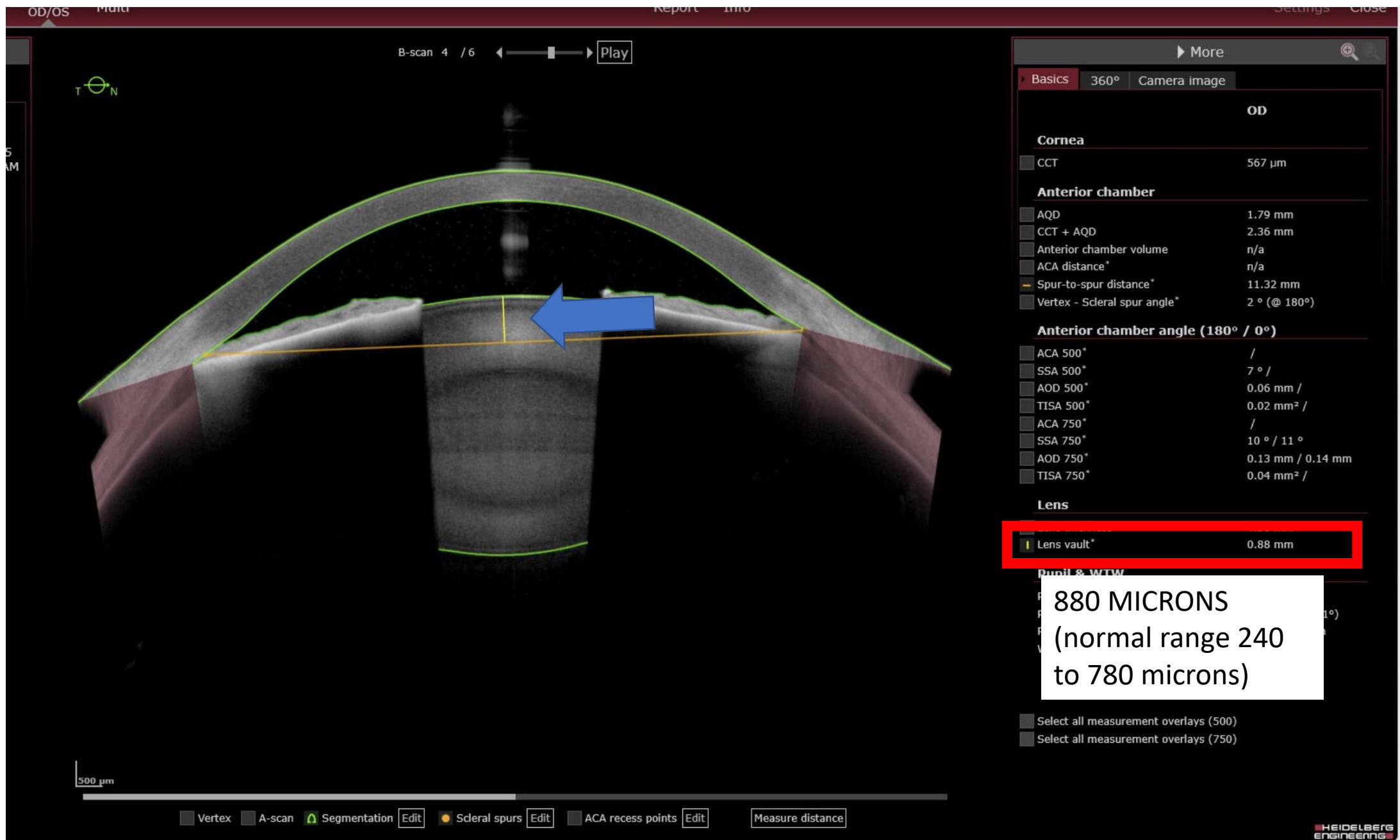


1:1 pixel 1:1 μm

Peripapillary RNFLT Classification



03/09/2025, OS
IR&OCT 30° ART



OD	
Cornea	
CCT	567 µm
Anterior chamber	
AQD	1.79 mm
CCT + AQD	2.36 mm
Anterior chamber volume	n/a
ACA distance*	n/a
Spur-to-spur distance*	11.32 mm
Vertex - Scleral spur angle*	2 ° (@ 180°)
Anterior chamber angle (180° / 0°)	
ACA 500*	/
SSA 500*	7 ° /
AOD 500*	0.06 mm /
TISA 500*	0.02 mm ² /
ACA 750*	/
SSA 750*	10 ° / 11 °
AOD 750*	0.13 mm / 0.14 mm
TISA 750*	0.04 mm ² /
Lens	
Lens vault*	0.88 mm

880 MICRONS
(normal range 240
to 780 microns)

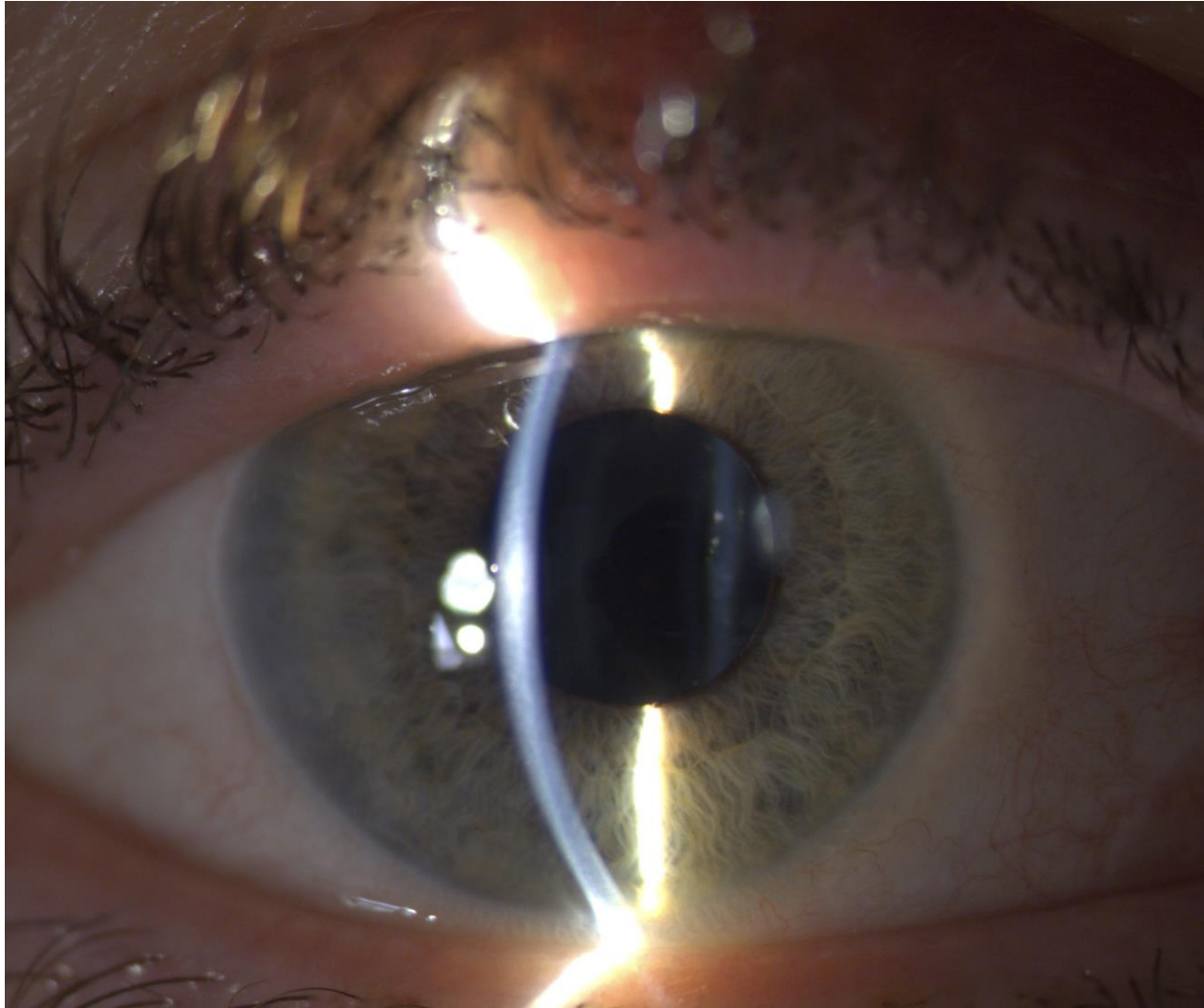
500 µm

Vertex A-scan Segmentation Edit Scleral spurs Edit ACA recess points Edit Measure distance



**APPOSITIONAL ANGLE CLOSURE
– PHACOMORPHIC**

After Cataract Surgery...



IOP 15

What about angle
closure patients
without cataract?



EFFECTIVENESS OF EARLY LENS EXTRACTION FOR THE TREATMENT OF PRIMARY ANGLE-CLOSURE GLAUCOMA: EAGLE TRIAL

Azuara-Blanco, A., et al., *Effectiveness of early lens extraction for the treatment of primary angle-closure glaucoma (EAGLE): a randomised controlled trial*. Lancet, 2016. 388(10052): p. 1389-1397.

Primary angle-closure glaucoma (PACG) is one of the leading cause of irreversible blindness

WORLDWIDE MULTICENTRE



**419 PHAKIC PARTICIPANTS
AGED >50 YEARS
30% Chinese**



**WITH PAC + >30mmHg IOP OR
PACG**

**Exclusion criteria: Symptomatic
cataract, advanced glaucoma,
previous acute angle closure attack,
previous laser or ocular surgery**

CLEAR LENS EXTRACTION VS. PERIPHERAL IRIDOTOMY



CLE n = 204



**PI n = 205
3 year Follow-up**



**HEALTH STATUS
(EQ-5D)**



EQ-5D 0.052 higher in CLE vs. PI



**INTRAOCULAR
PRESSURE**



IOP 1.18mmHg lower in CLE vs PI



**COST
EFFECTIVENESS**



**£14,284 per QALY gained for
CLE vs PI at 3 years**

**Additional surgery required in 1 vs 24
participants in favour of CLE**

Cataract Surgery in Glaucoma Patients is not straight forward!

- 5.2 Perform intra-operative management of the complex cataract

5.2.2 Utilise additional measures such as capsule stains and different types of ophthalmic viscoelastic devices to manage the complex cataract and recognise the effect that these measures may have on the intra-operative and post-operative course

5.2.3 Undertake management of risk from existing ocular conditions that may impact on cataract surgery including shallow anterior chamber, corneal opacity, iris defects, zonular defects or deficiencies, capsule defects or prior vitrectomy

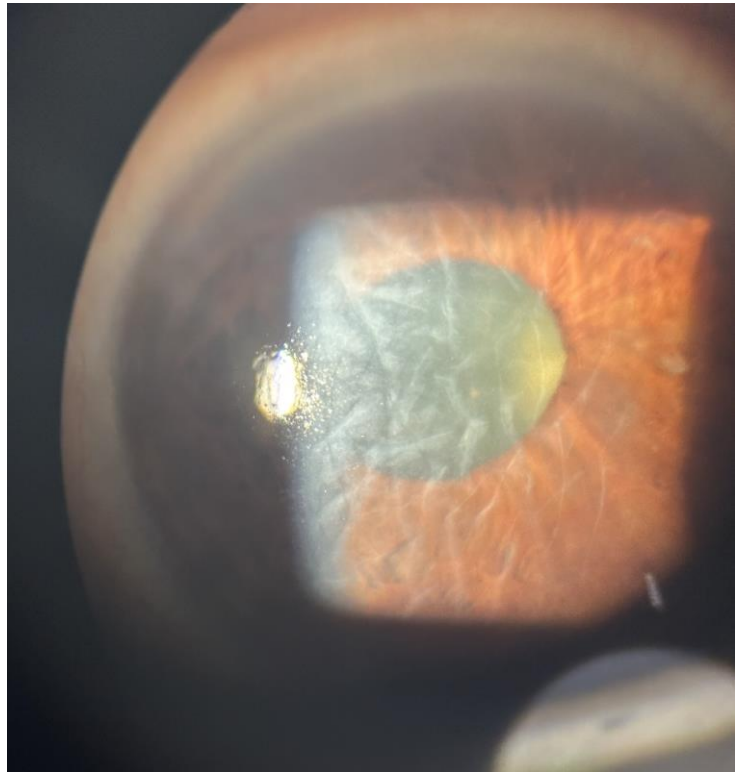
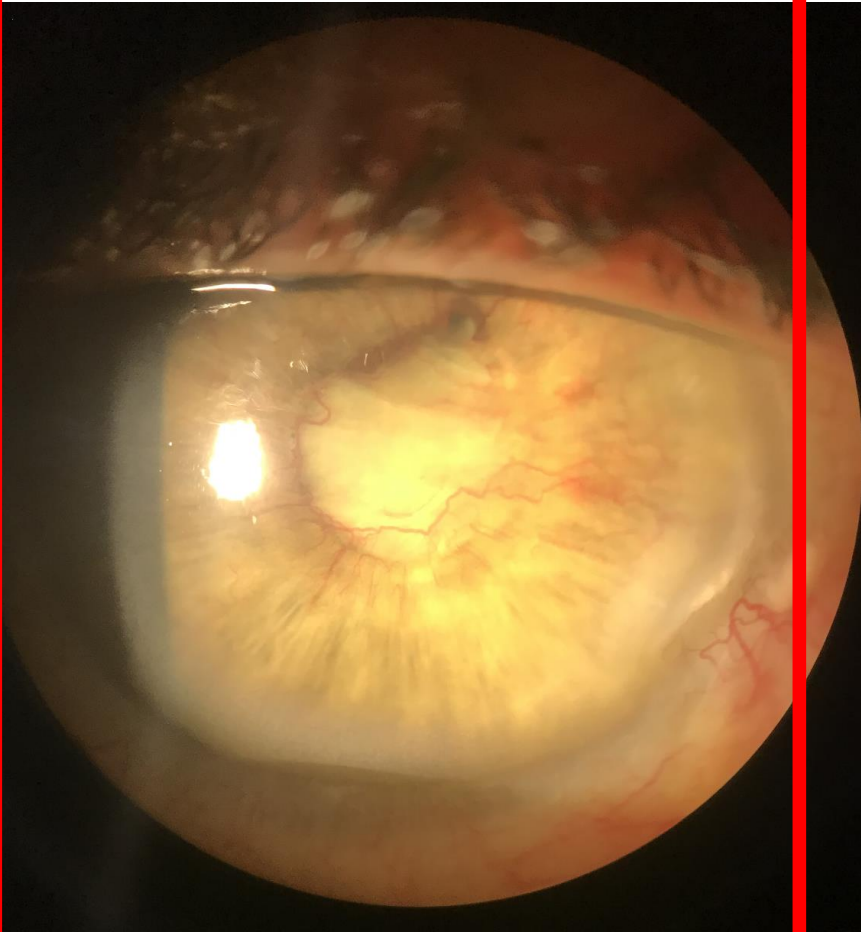
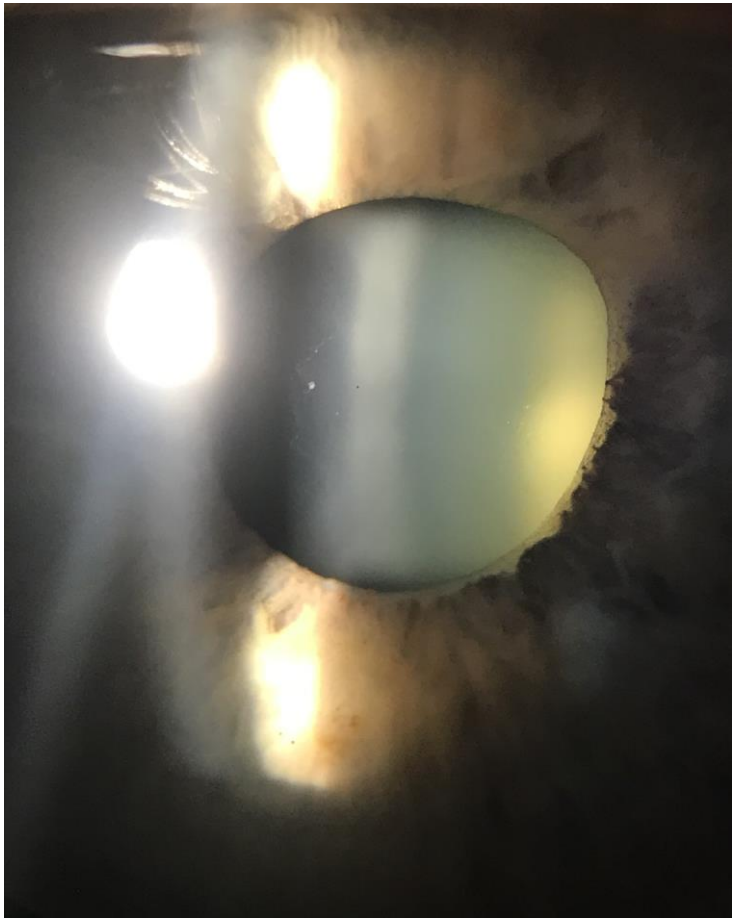
5.2.4 Repair and manage an iris defect including iris sutures and the implantation of iris prosthetic devices

Cataract Curriculum Standard

1 January 2022

This standard has been prepared by the Royal Australian and New Zealand College of Ophthalmologists (RANZCO) and is subject to copyright. Except as permitted under applicable legislation, no part of this document may be adapted, modified or reproduced by any process (electronic or otherwise) without the specific written permission of the copyright owner.

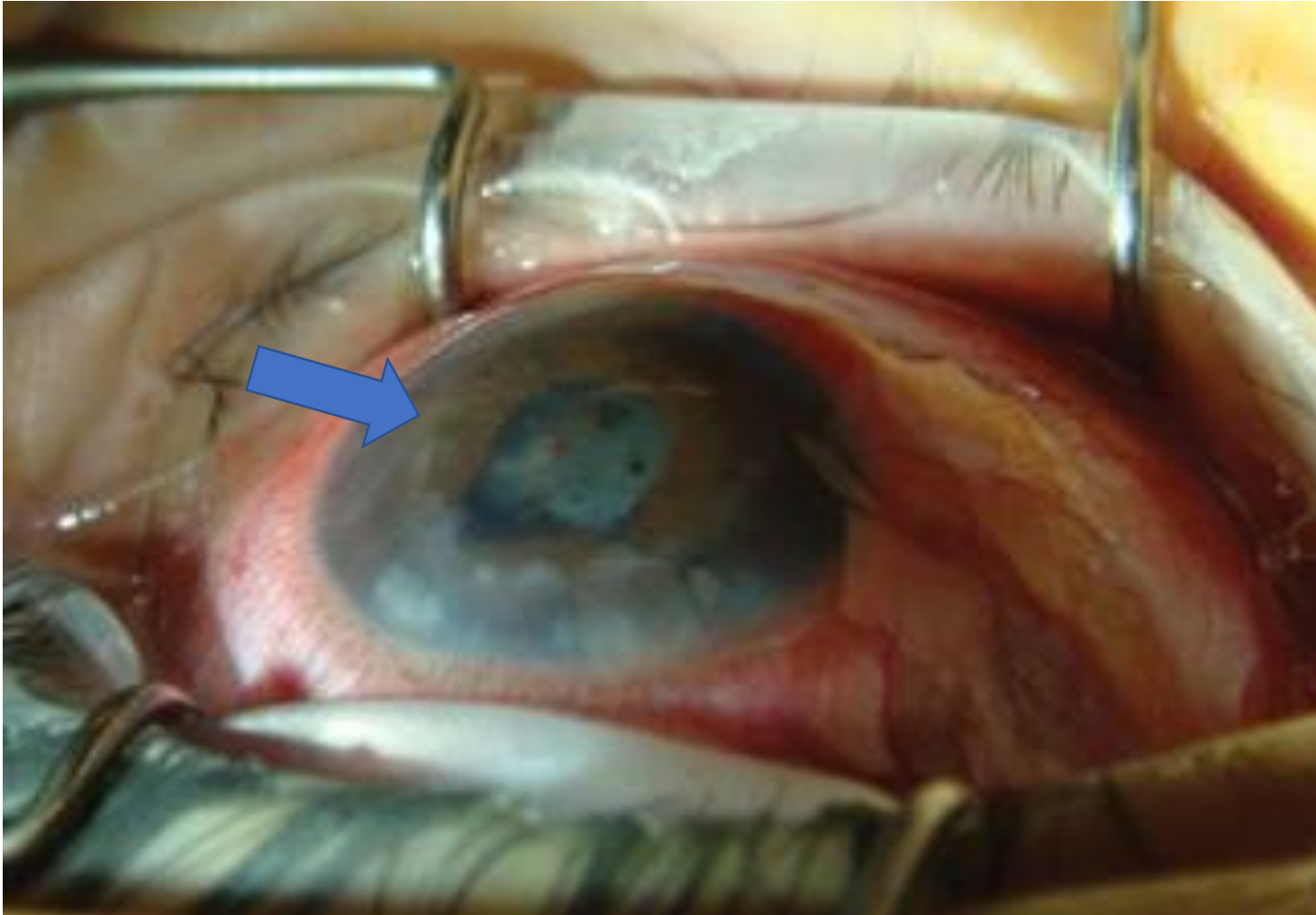





Why is surgery more difficult?

- **Ocular surface disease** → difficult access with sunken orbits, biometry variability
- **Poor pupil dilation** → synechiae, chronic miotic therapy
- **Secondary underlying associations** e.g pseudoexfoliation/ prior trauma
- **Higher complication risk** → e.g. zonular weakness and capsular rupture, increased risk of lens instability

Angle Closure Eyes— a risky proposition



(Your data will not be saved. Please print a copy for your record.) 

K INDEX 1.3375 K INDEX 1.332

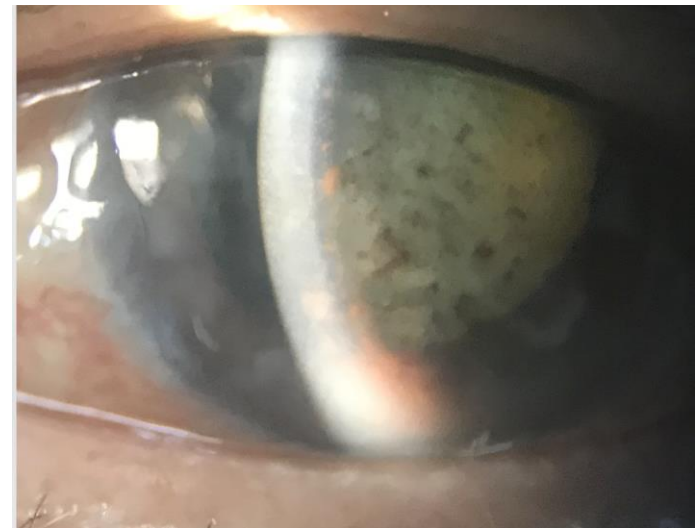Patient: CHEN ID: 1

Left Eye (OS):

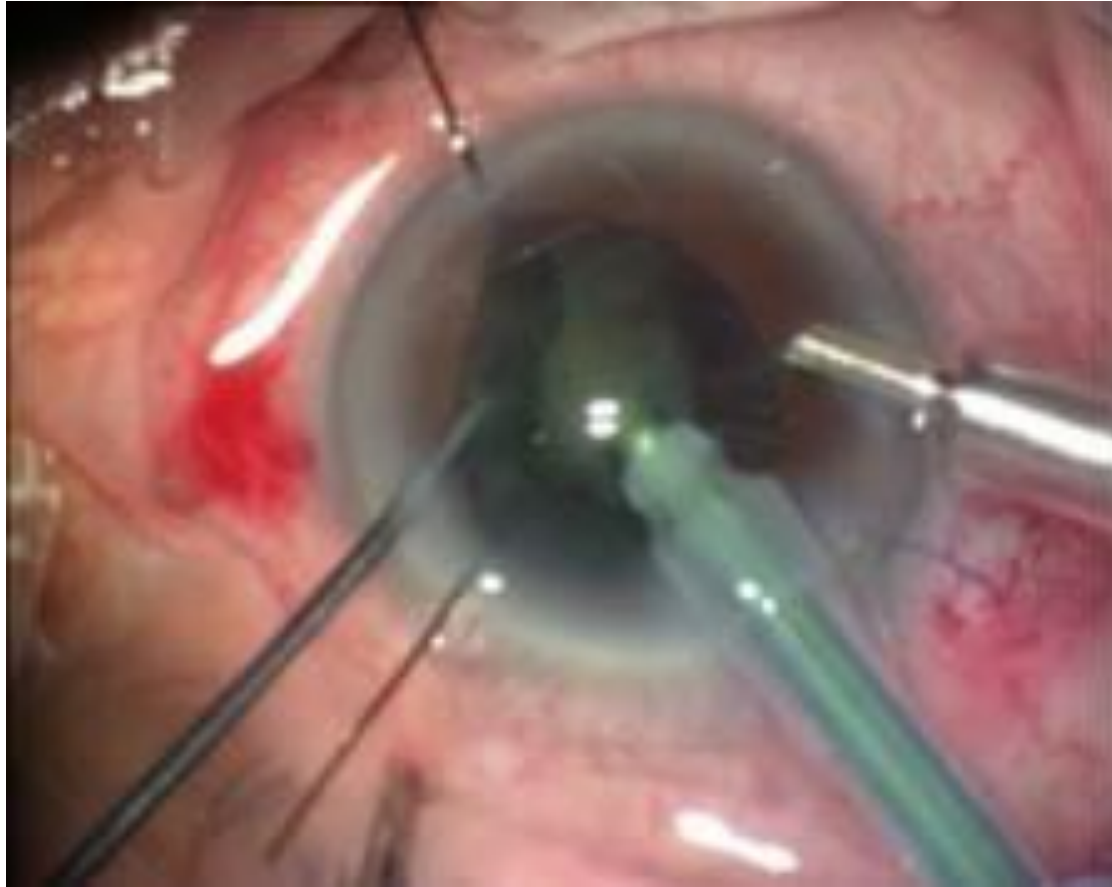Axial length: 22.22 Keratometry: K1: 48.35 K2: 46.11 ACD: 0.53

Recommended IOL: 20.42 (Biconvex) for Target Refraction: 0

Lens Factor: 2.09 A Constant: 119.39 WTW: 11.17 Lens Thickness:

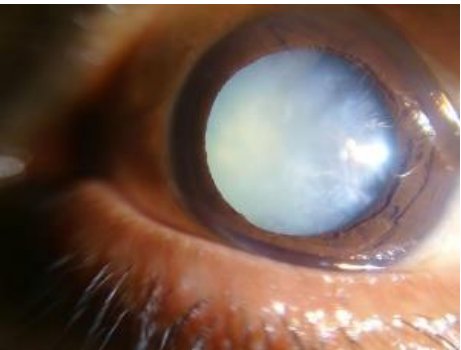


Angle Closure Eyes Are Stressful



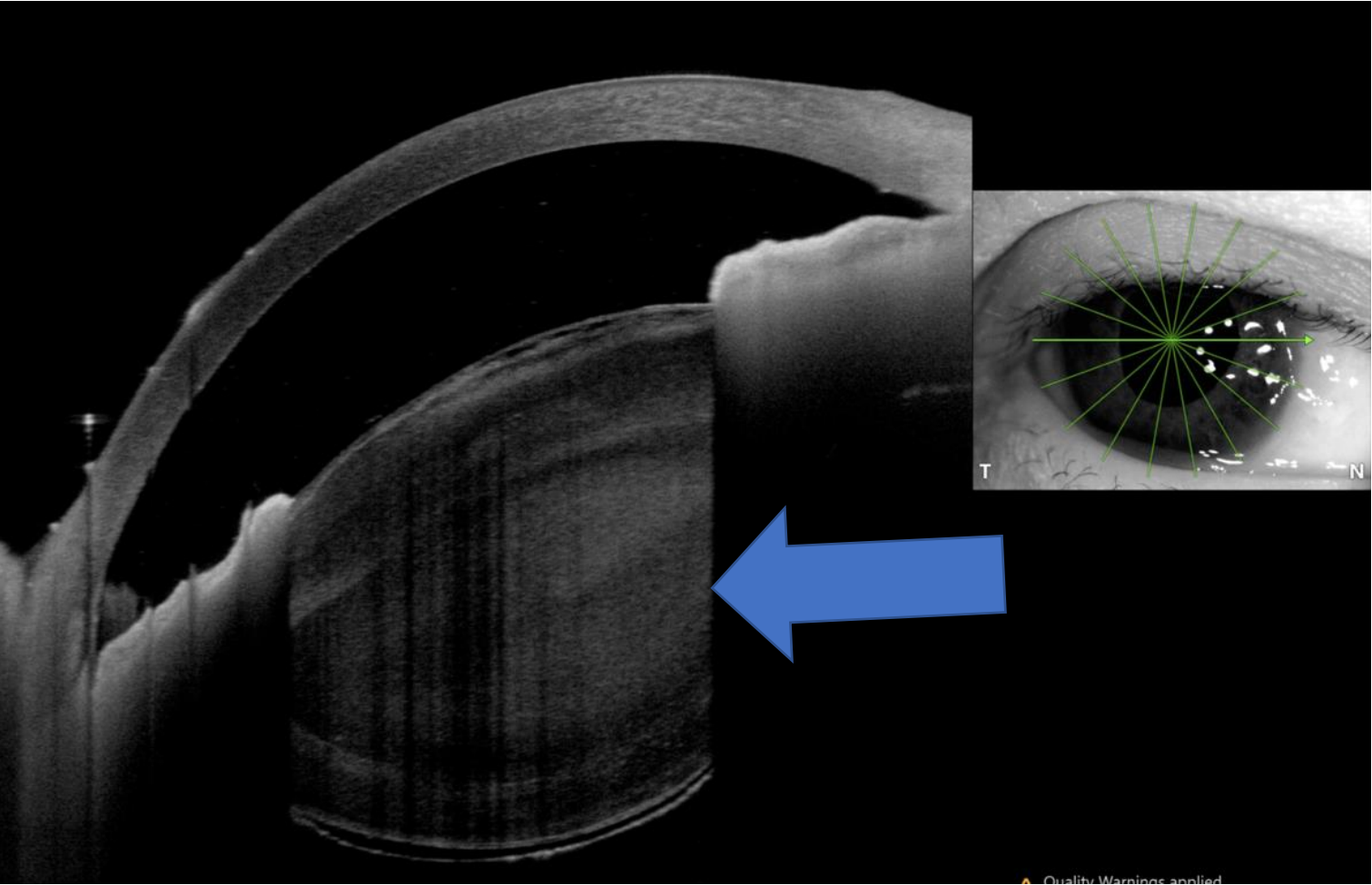
- No/poor view
- No zonules
- No anterior chamber
- Degenerate capsule
- Atonic pupil
- High risk of vitreous loss

50 yo Afrocarribean female RIGHT AACG



Examination		
OD		OS
No Perception Light	VA (aided)	6/7.5 +
48	IOP	22
White	Sclera & Conj	white
Mild oedema	Cornea	clear
Shallow, 1+ cells. ?PAS	AC	d + q
NS2-3+	Lens	NS 2+

Anterior Chamber Depth 1.8 mm



10/08/23 1/5214

iop check Anterior Segment

? secondary chronic Ac glaucoma (R) eye
(R) sup 71 31/07/23

OCT

Department	eye clinic	
Patient:	Identified	<input checked="" type="checkbox"/>
	Treatment Discussed	<input checked="" type="checkbox"/>
	Consented for Treatment	<input checked="" type="checkbox"/>
Name:	IRENE PATEL	Signature: al
Designation:	20	Date: 10/08/23

Aided / Unaided vision

R: 6/12 L: 6/7.5 ⁻²

PH: R: L: N/A

IOP @ 11:00 iCare

R: 19 L: 03

Challenges. DOM @ smolar
meds. q Azarga Bd (R) eye
q Xalatan daily (R) eye
maxidex aid
PO Diamox 250mg daily

App @ 11:15am
/ \

22 19

R) dense NS
No obvious phacodonesis but
VAs

P (Proceed) plan +10L
guarded prognosis
→ surgery doc for
preventing downstream
complications (e.g phacolytic
glaucoma)

- EYE CLINIC NEXT VISIT
- AUTO REFRACT
- DILATE R L
- TOPOGRAPHY WVF
- OCT MAC OCT RNFL
- HOL
- OTHER _____

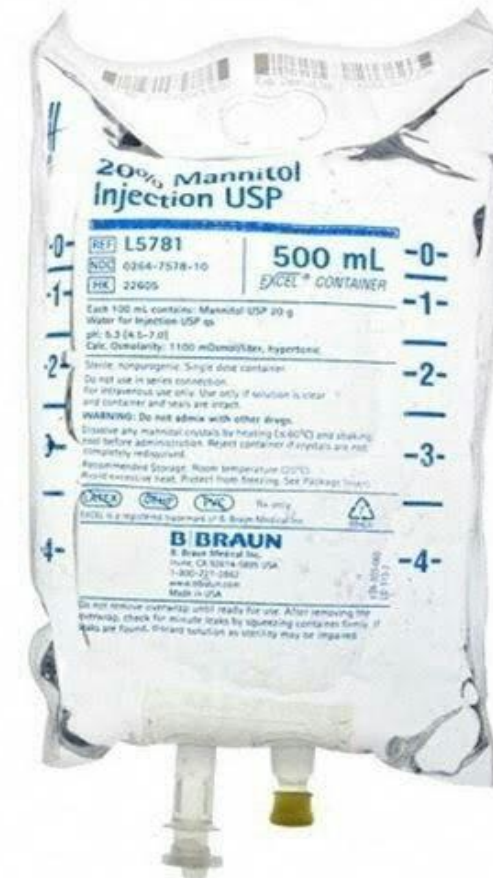SIGNED _____

OPHTHALMIC NOTES

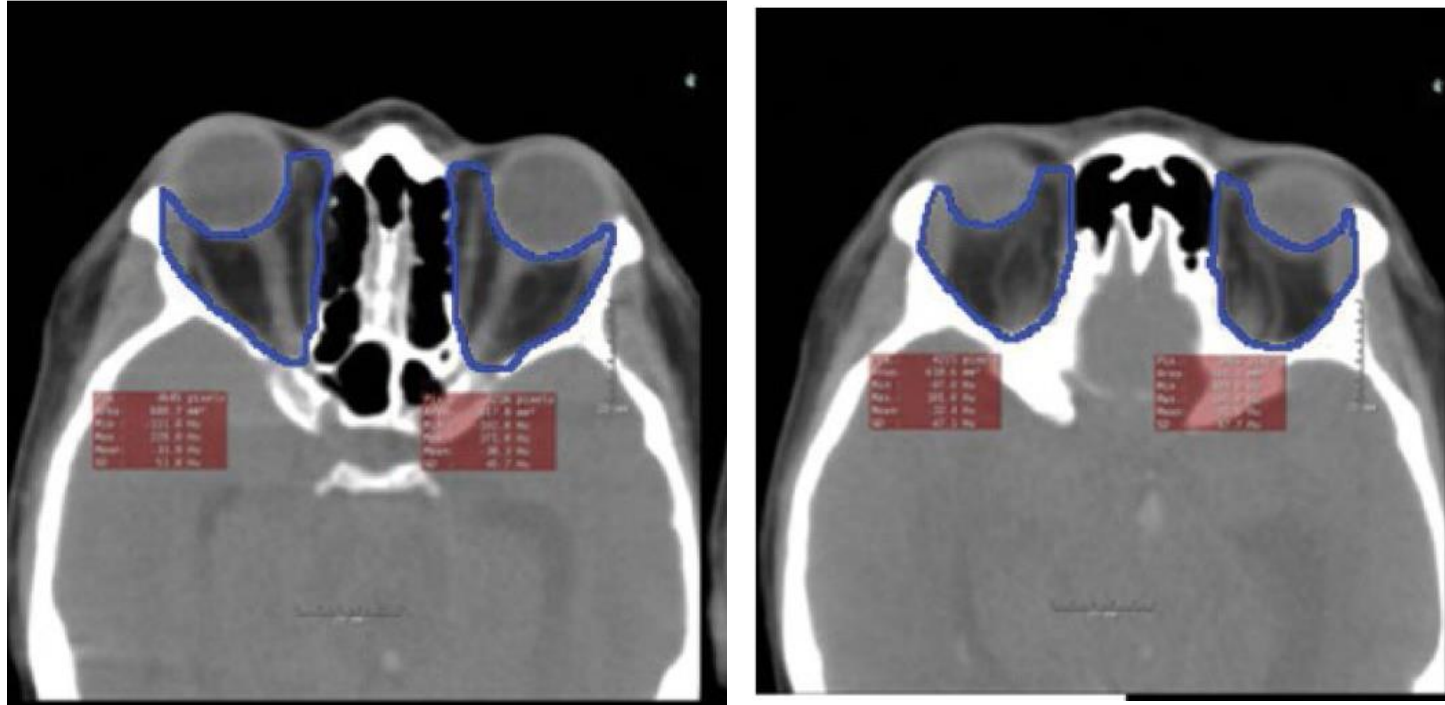
MR 3

Preoperative IV Mannitol

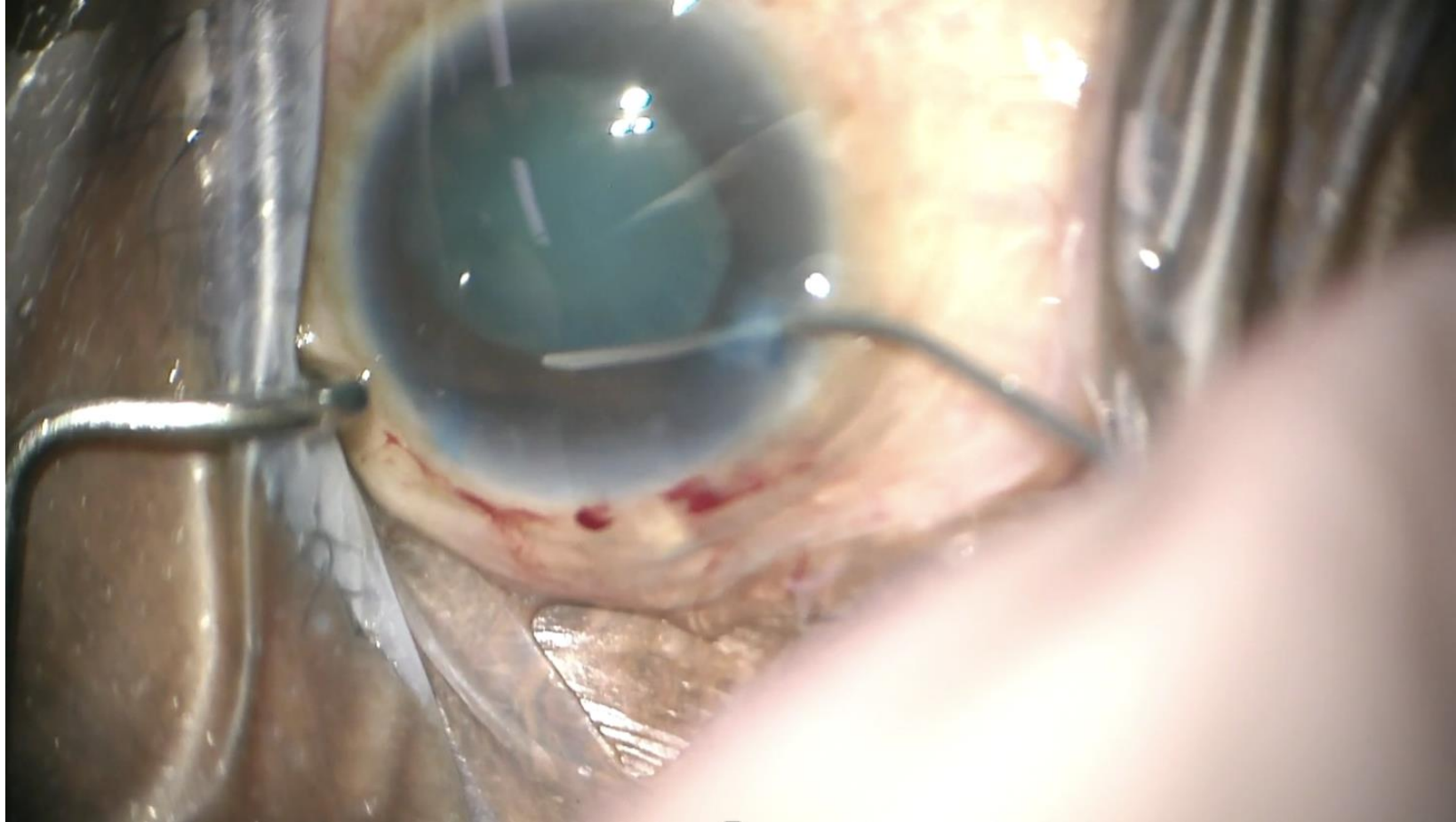- Osmotic diuretic
- Dosages typically range from 1.5 to 2 g/kg
- Administered intravenously over 30 to 60 minutes
- Effect within 5 to 10 minutes and lasting up to approximately 6 hours.



Mannitol can be used to reduce vitreous volume



Average globe volume decreased 186 mm³ (-2.5%, p = 0.02) after mannitol administration, while average orbital volume increased 353 mm³ (+3.5%, p = 0.04).



Angle closure cataract surgery

Potentially complicated surgery!

- You will see these patients in clinic
- Guarded visual prognosis
- High risk of refractive surprise
 - Unpredictability in final effective lens position

Title: Prediction of Post-phacoemulsification Anterior Chamber Depth of Chronic Primary Angle-closure Glaucoma: Use of a Machine Learning Method.

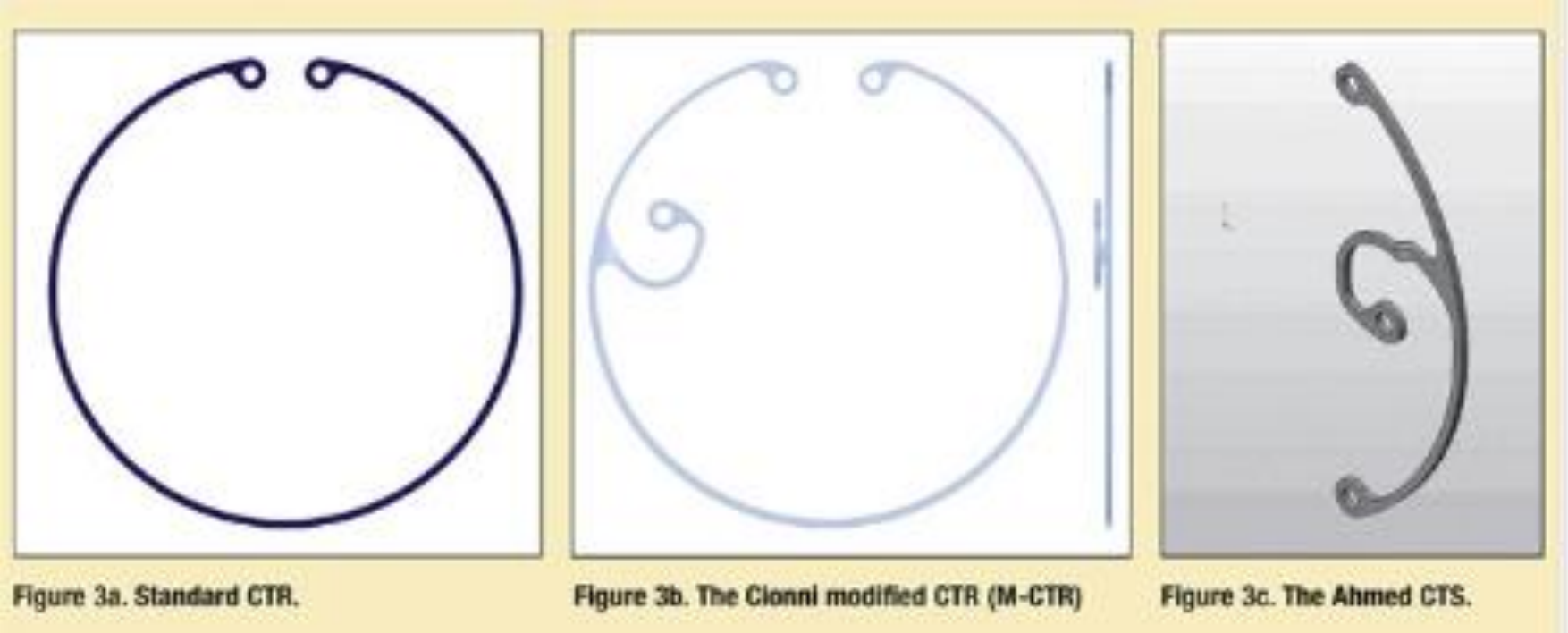
Author list:

Yingying Zheng ^{1,2,3} #,
Xinyuan Liu ^{1,2,3} #,
~~Qiyang~~ Ge ⁴,
Yuhong Chen ^{1,2,3},
~~Jiajian~~ Wang ^{1,2,3},
Yi DAI ^{1,2,3},
Xiangmei Kong ^{1,2,3},
Li Wang ^{1,2,3},
Yuan Fang ^{1,2,3},
~~Xueli~~ Chen ^{1,2,3},
Feng Gao ^{1,2,3},
Junyi Chen ^{1,2,3},
Geoffrey Chan, ^{5,6}
~~Xinghuai~~ Sun ^{1,2,3,7} =
Yun Yuan ⁸ =
Hongfang Yang ^{1,2,3}

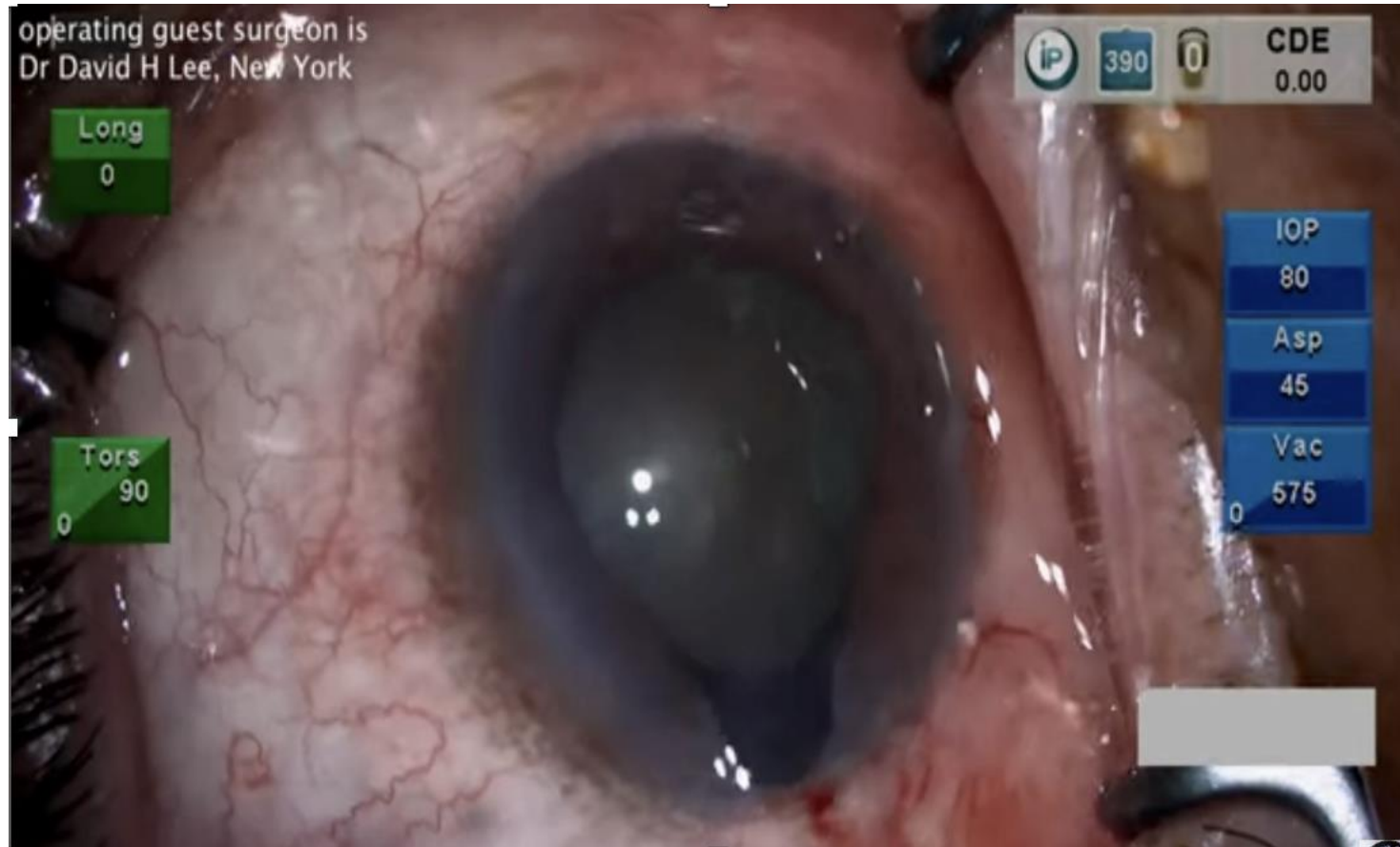Affiliations:

1. Eye Institute and Department of Ophthalmology, Eye & ENT Hospital, Fudan University, Shanghai 200031, China
2. NHC Key laboratory of Myopia and Related Eye Diseases; Key Laboratory of Myopia and Related Eye Diseases, Chinese Academy of Medical Sciences, Shanghai, 200031, China
3. Shanghai Key Laboratory of Visual Impairment and Restoration, Shanghai, 200031, China

Zonular Support




Intraoperative Aqueous Misdirection

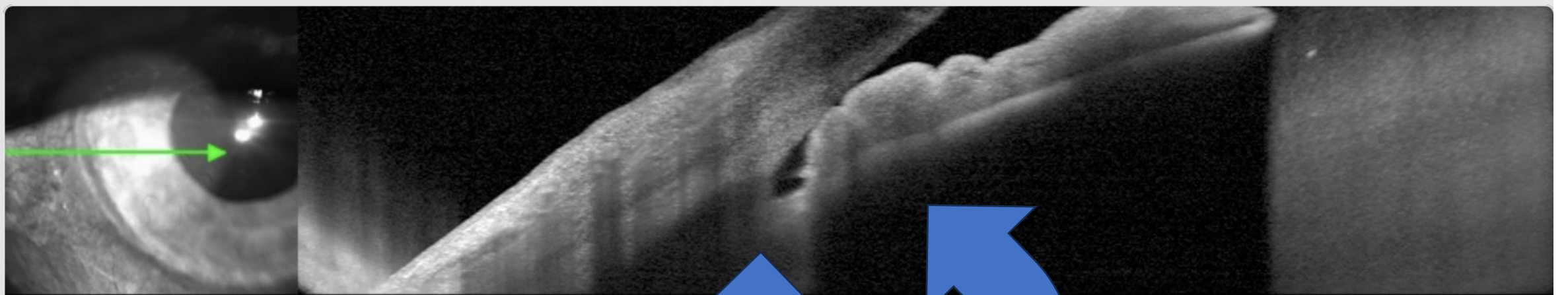


- AC becomes shallow/flat
- High IOP
- Iris prolapse

Cataract Surgery & Intraoperative Aqueous Misdirection



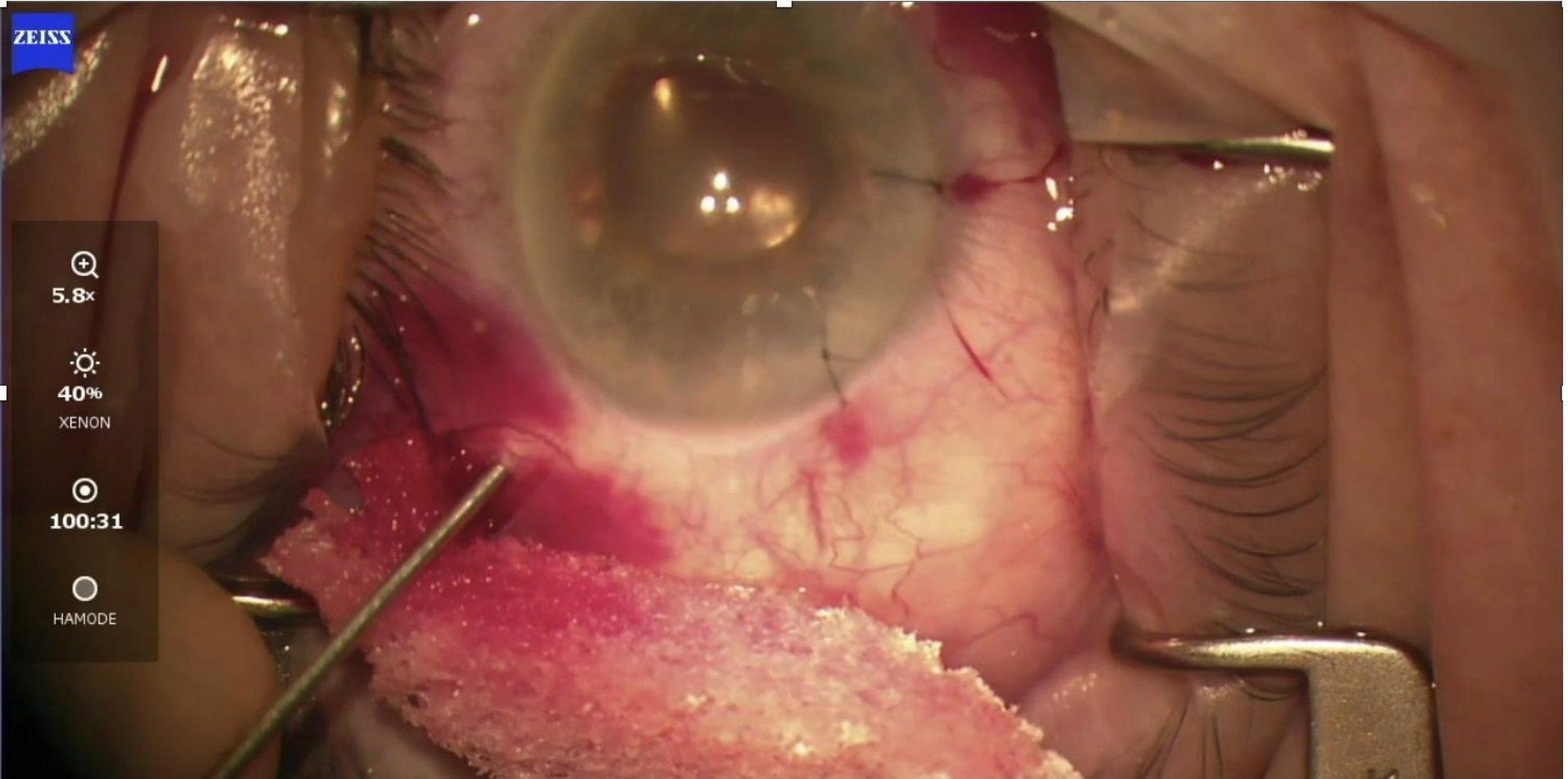




1/03/2024, OD

IR&OCT 20° ART EDI [HR] ART(60) Q: 37

HEIDELBERG
ENGINEERING



ZEISS

5.8x

40%
XENON

100:31

HAMODE

Iris Prolapse...sometimes you just can't help it...

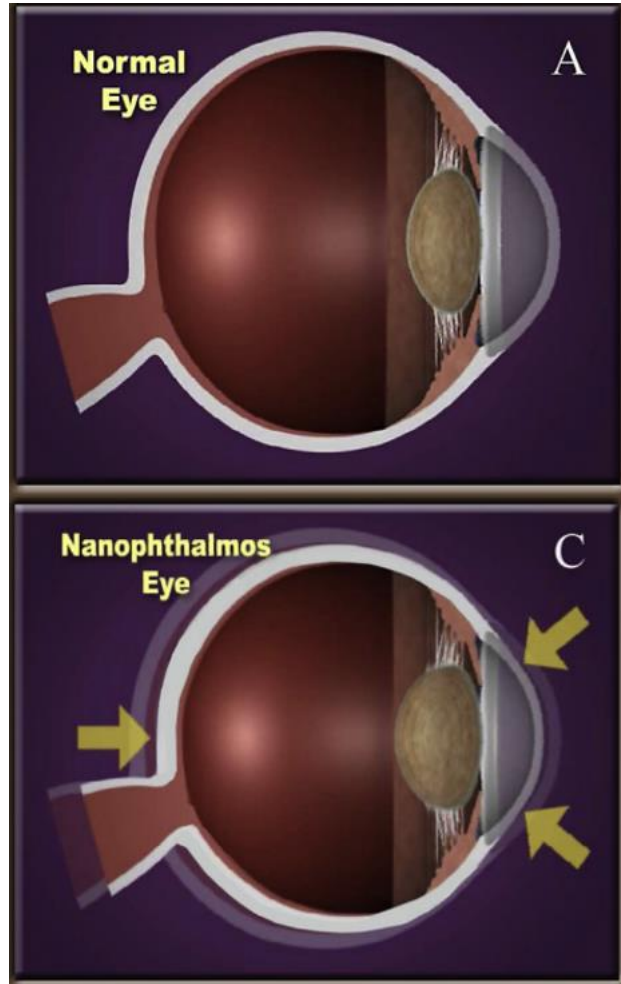
OD right		IOL calculation		OS left	
☹				☹	
Eye status					
LS: Phakic		VS: Vitreous body		LS: Phakic	
Ref: ---		VA: ---		Ref: ---	
LVC: Untreated		LVC mode: -		LVC: Untreated	
LVC mode: -				LVC mode: -	
Biometric values					
AL: 20.38 mm		SD: 7 µm		AL: 19.99 mm	
ACD: 1.87 mm		SD: 5 µm		ACD: 1.91 mm	
WTW: 11.7 mm				WTW: 11.6 mm	
SE: 42.87 D		SD: 0.01 D		SE: 43.47 D	
ΔK: -0.75 D @ 5°		K1: 42.50 D @ 5°		SD: 0.00 D	
TSE: ---		K2: 43.25 D @ 95°		K1: 42.52 D @ 171°	
ΔTK: ---		TK1: ---		K2: 44.47 D @ 81°	
		TK2: ---		TK1: ---	
				TK2: ---	
K Bausch&Lomb EyeCee One		K Alcon SN60WF		K Bausch&Lomb EyeCee One	
- Hoffer® Q -		- Hoffer® Q -		- Hoffer® Q -	
pACD: +5.71		pACD: +5.64		pACD: +5.71	
IOL (D) Ref (D)		IOL (D) Ref (D)		IOL (D) Ref (D)	
+36.00 -0.68		---		+37.50 -0.91	
+35.50 -0.32		---		+37.00 -0.54	
+35.00 +0.04		---		+36.50 -0.18	
+34.50 +0.40		---		+36.00 +0.18	
+34.00 +0.75		---		+35.50 +0.53	
+35.06 Emmetropia		+34.81 Emmetropia		+36.25 Emmetropia	
K Alcon AcrySof MA60AC		K Alcon MTA-Series		K Alcon AcrySof MA60AC	
- Hoffer® Q -		- Hoffer® Q -		- Hoffer® Q -	
pACD: +5.67		pACD: +3.16		pACD: +5.67	
IOL (D) Ref (D)		IOL (D) Ref (D)		IOL (D) Ref (D)	
---		+28.50 -0.91		---	
---		+28.00 -0.47		---	
---		+27.50 -0.03		+28.50 -1.08	
---		+27.00 +0.39		+29.00 -0.64	
---		+26.50 +0.82		+28.50 -0.20	
+34.91 Emmetropia		+27.46 Emmetropia		+28.00 +0.23	
				+27.50 +0.66	
				+36.10 Emmetropia	
				+28.27 Emmetropia	

version 01 00000001 - copyright 2014 All rights reserved

(!) Borderline value

(*) Value was edited manually

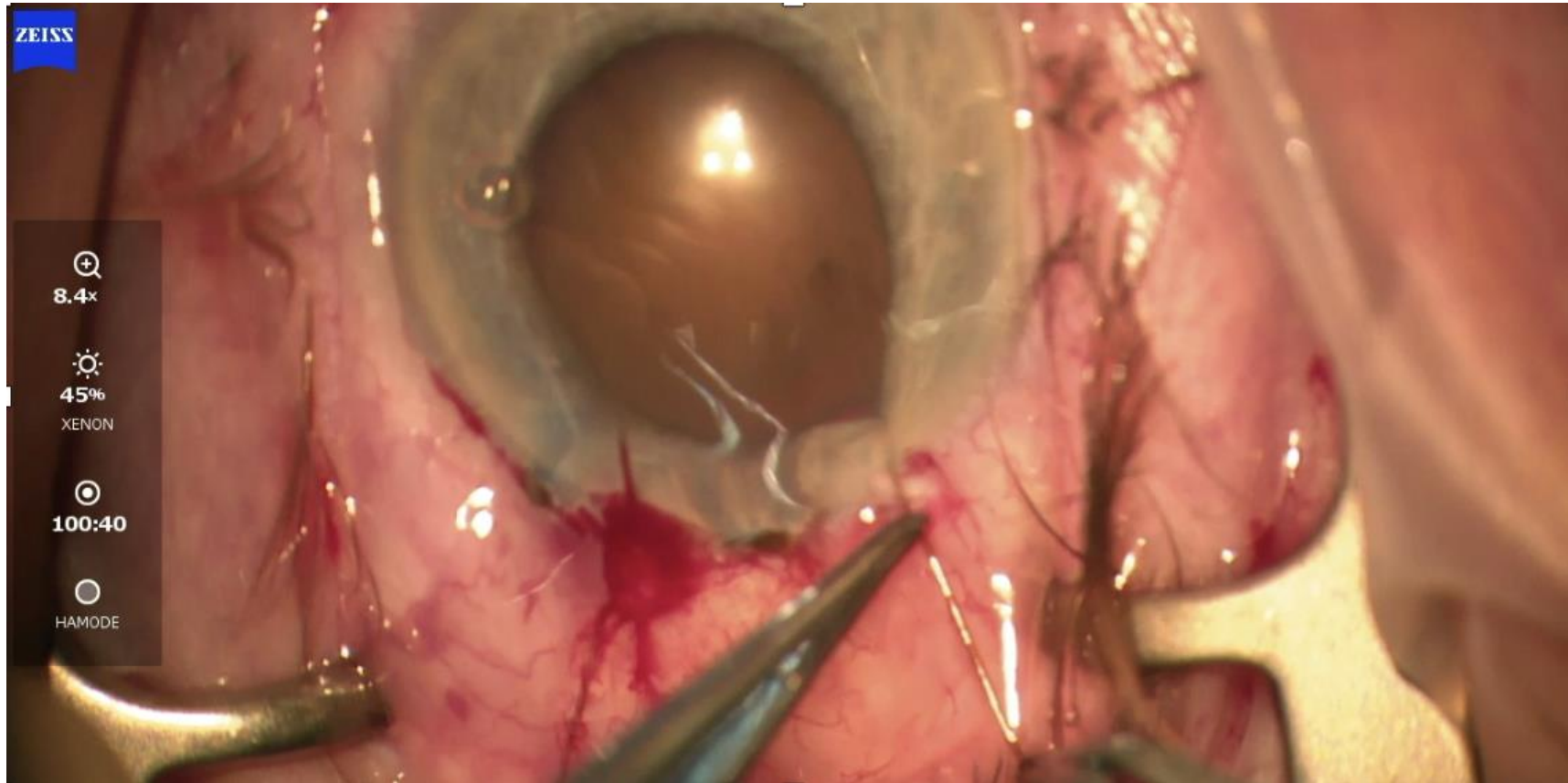
--- No value measured



Nanophthalmos is diagnosed primarily by axial length, with cut-offs in the literature including:

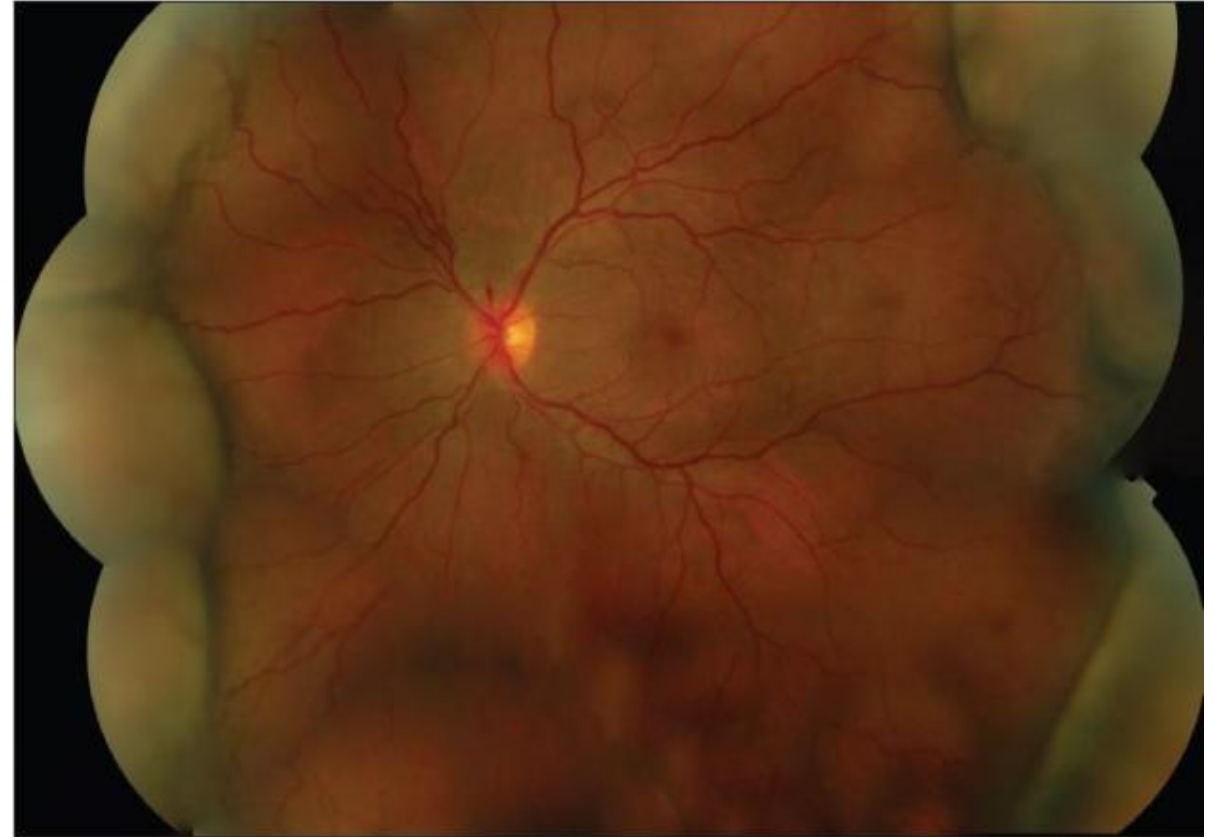- <18.0 mm
 - <20.5 mm
 - <21.0 mm
- Scleral thickening or combined retinal-choroidal-scleral thickening is used as an additional diagnostic criterion in some studies.

Nanophthalmos with previous Acute Primary Angle Closure



Cataract surgery in Small Glaucomatous eyes

- Surgically challenging
 - Corneal decompensation
 - Uveal effusions (3.2 to 50%)
 - Aqueous misdirection
 - Cystoid macular edema
 - Suprachoroidal haemorrhage
 - Vitreous haemorrhage
 - Retinal detachment



Analyze

Eye status


LS: --- VS: Vitreous body LVC: Untreated
 Ref: --- VA: ---

Biometric values


AL: 16.49 mm	SD: 7 μm	WTW: 11.2 mm	Ix: +0.4 mm	Iy: +0.3 mm
CCT: 551 μm	SD: 4 μm	P: 3.9 mm	CW-Chord: 0.6 mm @ 229°	
ACD: 1.74 mm	SD: 3 μm			
LT: 5.06 mm	SD: 6 μm			

SE: 50.15 D	SD: 0.03 D	TSE: ---
K1: 49.78 D @ 68°	SD: 0.03 D	TK1: ---
K2: 50.52 D @ 158°	SD: 0.03 D	TK2: ---
ΔK: -0.74 D @ 68°		ΔTK: ---


B scan



Keratometry

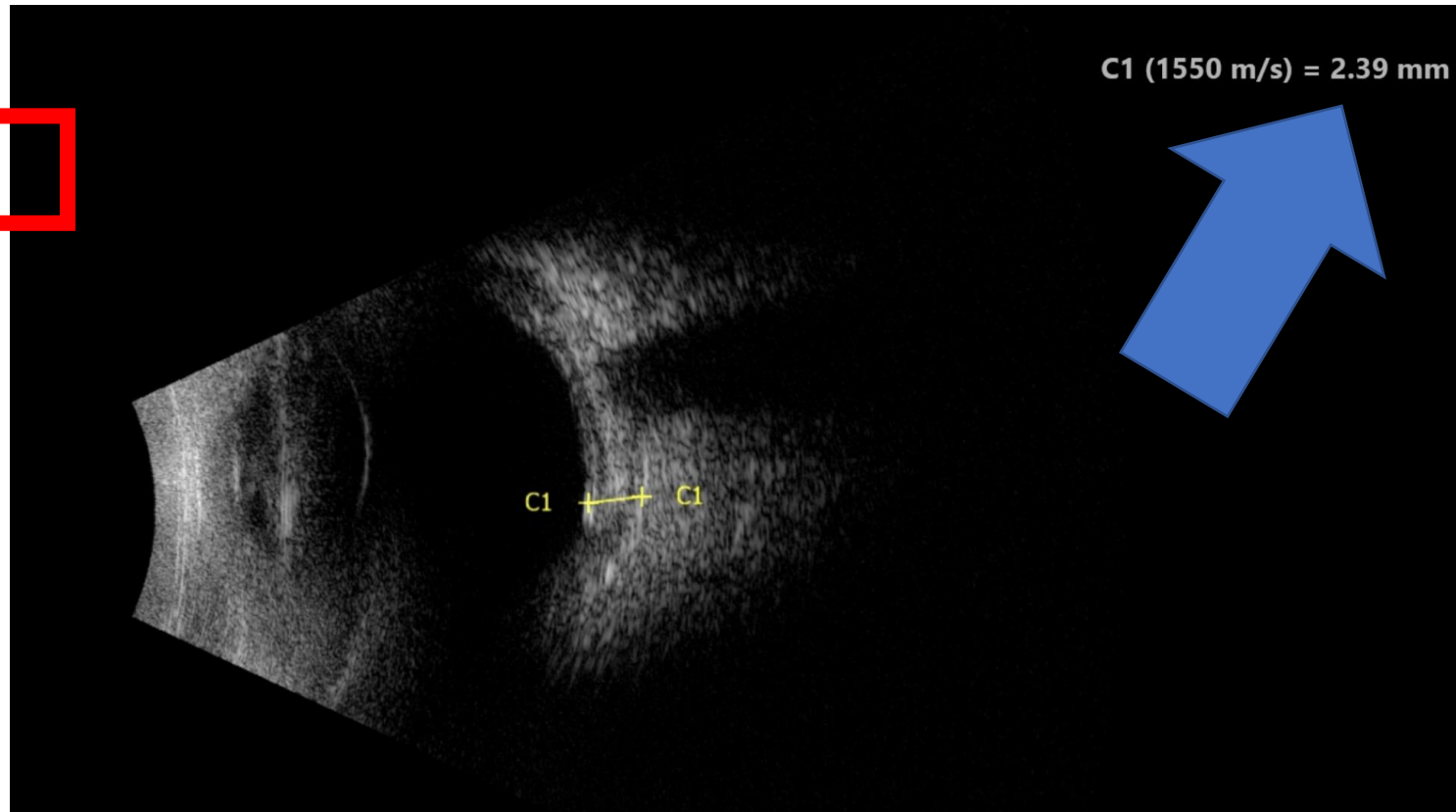


White-to-white

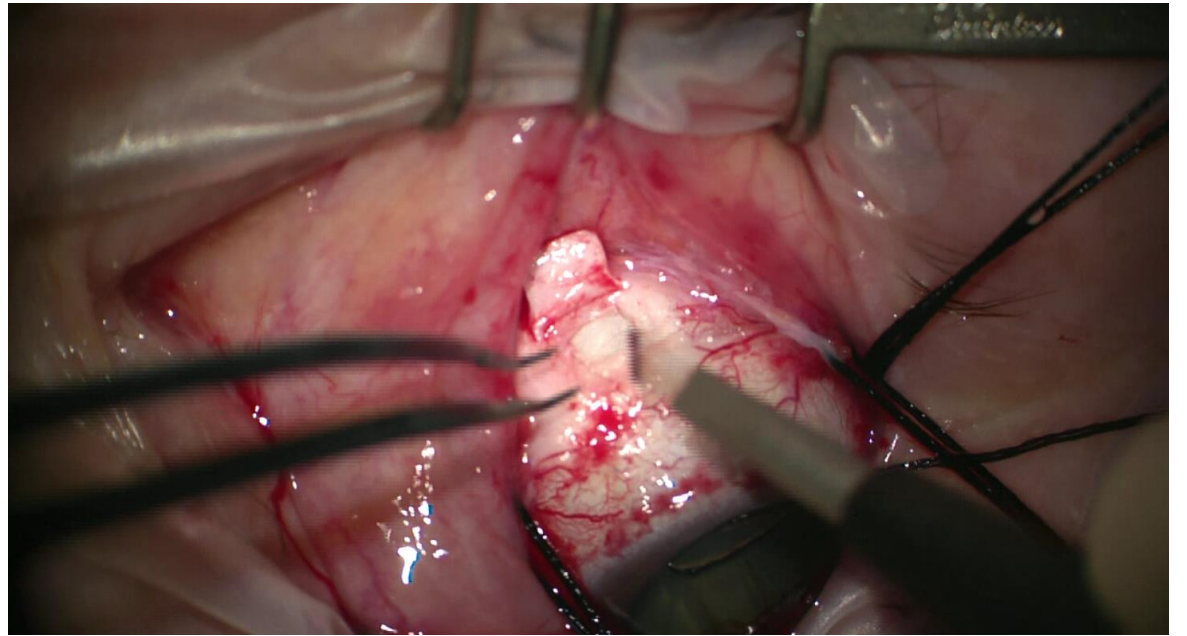
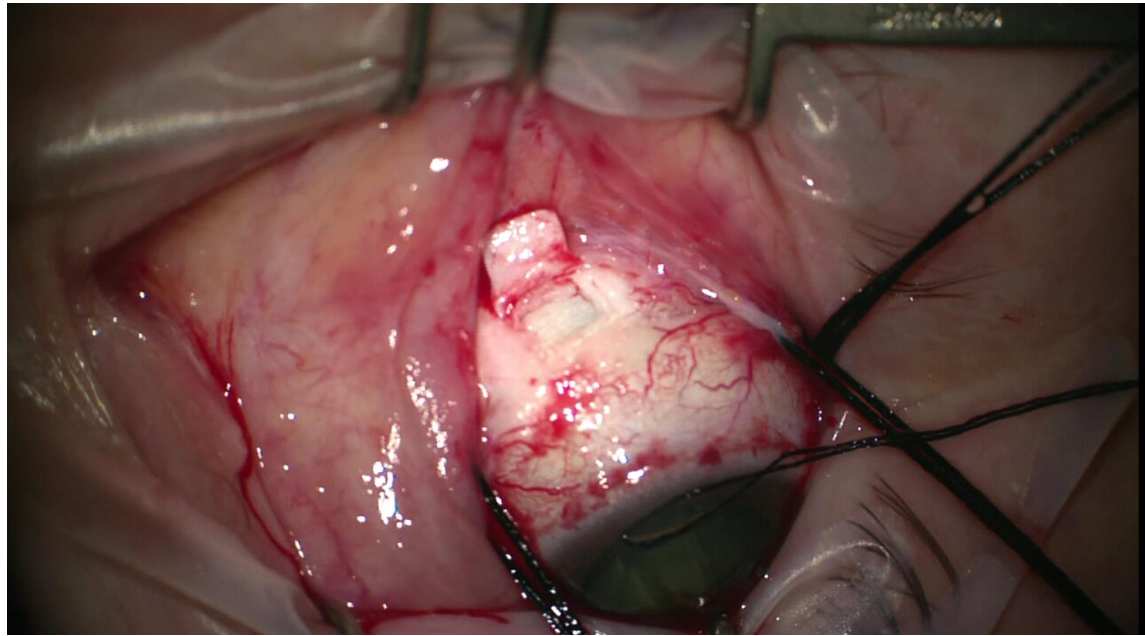


Fixation

(†) Borderline value (*) Value was edited manually --- No value measured



Preoperative scleral windows



IOI Selection in Glaucoma Patients

- **Monofocal IOIs** preferred to preserve contrast sensitivity in glaucoma patients.
- **Multifocal/EDOF IOIs** may worsen contrast and night vision
 - Use cautiously in mild glaucoma.
- **Toric IOIs** can correct astigmatism but consider ocular surface and glaucoma stability.
- **IOI choice** should align with glaucoma severity and potential future surgery.

D P X H C B
Y P T U A G
A E L S O I
O C R M E U
K T I E D L
X R P O K A
H Q D Y T N
G A U N P S

Take Away Messages

- Bidirectional relationship between cataract and glaucoma
- These eyes are surgically challenging
 - Especially Angle Closure
- Meticulous preoperative planning and intervention
- Screening patients and early referral is critical

